

# Anticarcinogenic potential of *Withania coagulans* fruit against skin papillomagenesis in swiss albino mice

Deepika Mathur\* and R.C Agrawal

Dept. of Research, Jawaharlal Nehru Cancer Hospital and Research Centre, Bhopal (M.P), India.

## Abstract

*Withania coagulans* belongs to family Solanaceae and its berries are commonly known to be as good vegetable rennet. It has been reported to have withanolides which are known to be as a group of steroidal lactones found among members of Solanaceae. Withanolides are reported to have antitumor, antibacterial, anti-inflammatory, immune-suppressive, cyto-toxicity and antiulcer activities. In the present study, the anti-carcinogenic activity of *Withania coagulans* of aqueous and methanolic fruit extracts was investigated on DMBA induced skin papillomagenesis. Single topical application of 7,12-dimethylbenzanthracene (DMBA) of 100µg/100µl acetone, was given and one week later promoted by repeated application of Croton oil (1% in acetone/twice in a week ) till the end of experiment (16 weeks) in *Swiss albino* mice. Single topical application of Methanolic and Aqueous extract of *Withania coagulans* at the dose 1000mg/kg body weight along with DMBA+ Croton oil was found effective in decreasing cumulative no. of papillomas, tumor yield, tumor incidence and tumor burden as compared to the Control group i.e. DMBA and Croton oil. Histo-pathological studies also showed positive results of the *Withania coagulans* extracts against DMBA as promoter and Croton oil as stimulator of causing papillomagenesis. Histological sections in all the groups show marked papillomatosis, hypergranulosis and hyperkeratosis with papillary projections but in the control group papilloma consisted of fibro-vascular core with lump of epithelia showing mild dysplasia, the signs of malignancy were prominent showing Keratinous pearl and full thick dysplasia containing fibro-vascular core with lining epithelia. The tumor incidence in methanolic extract group are found statistically significant ( $p < 0.05$ ) in comparison to control group.

**Keywords:** Anti-carcinogenicity, DMBA, *Withania coagulans*, papilloma, skin papillomagenesis.

## INTRODUCTION

*Withania coagulans* Dunal belongs to family Solanaceae. *Withania* is a small genus of shrubs, which are distributed in the East of the Mediterranean region and extends to South Asia. It is commonly found in Pakistan. The berries of the shrub are used for milk coagulation. The main components of berries are esterases, fatty oil, amino acids (such as proline, hydroxyproline, valine, tyrosine, aspartic acid, glycines, asparagines, cystine and glutamic acid) and alkaloids are the phytoconstituents [1]. *Withania coagulans* Dunal is used to treat nervous exhaustion, debility, insomnia, wasting diseases, failure to thrive in children, impotence. Its fruits are used for liver complaints, asthma and biliousness. Flowers of *coagulans* Dunal are used in the treatment of diabetes [2]. The plant has been reported to have withanolides which are known to be as a group of steroidal lactones found amongst members of solanaceae. Withanolides are reported to have antitumor [3], antibacterial [4], anti-inflammatory [3], immuno-suppressive [5], cyto-toxicity and antiulcer activities [6, 7]. We have therefore carried out studies to investigate the anti-carcinogenic potential of *Withania coagulans*, methanolic

and aqueous extracts using skin papilloma model on Experimental animals.

## MATERIALS AND METHODS

### Chemicals

DMBA and Croton Oil were procured from Sigma Chemicals Co. (St. Louis, MO). DMBA was dissolved at a concentration of 1mg/ml in Acetone. Croton oil was prepared by mixing in Acetone.

### Extracts preparation

The plant *Withania coagulans* was identified by the competent botanist of Bhopal. The fruits were purchased from Medicinal shops of Bhopal and shade dried followed by grinding. Aqueous Extract was prepared by taking double distilled water in Soxhlet apparatus at 60°C. While 100% Methanolic extract was prepared by separating funnel refluxing for 36 hrs at 50-60°C. The dried extract pellets were obtained and extract was prepared at a dose level of 500 and 1000mg/kg body weight.

### Experiment Protocol

Three days before the commencement of the experiment, hair on the inter-capsular region of the mice were shaved. The mice showing lack of hair growth on the shaved region were only selected for the study. The animals were randomly selected for 12 groups comprising of 6 mice each. The treatment was given according to the

\*Corresponding Author

Deepika Mathur  
Dept. of Research, Jawaharlal Nehru Cancer Hospital and Research Centre,  
Bhopal (M.P), India.

Email: [deepika11.mathur@gmail.com](mailto:deepika11.mathur@gmail.com)

method as prescribed [8].

### Treatment Groups

**Group 1 (Untreated control)** - No treatment

**Group 2 (Vehicle Control)** - 100µl acetone 2 times/ week up to 16 weeks.

**Group 3 (DMBA alone)**-100µg DMBA was dissolved in 100µl acetone and single application was given.

**Group 4 (Croton oil alone)**-1% Croton oil was applied on the skin 2 times a week up to 16 weeks.

**Group 5 (DMBA+Croton oil)**-100µg DMBA was dissolved in 100µl acetone and single application was given afterwards, 1% Croton oil was applied on skin 2 times a week up to 16 weeks.

**Group 6 (DMBA+W.coagulans fruit aqueous extract + Croton oil)**- 100µg DMBA was dissolved in 100µl acetone and single application was given afterwards the 100µl dose of *W. coagulans* fruit aqueous extract at the dose of 1000mg/kg b.wt. dose was given one hour before each application of 1% Croton oil 2 times a week up to 16 weeks.

**Group 7 (DMBA+ *W. coagulans* fruit Methanolic extract + Croton oil)**- 100µg DMBA was dissolved in 100µl acetone and single application was given afterwards the 100µl dose of *W. coagulans* fruit Methanolic extract at the dose of 1000mg/kg b.wt. was given one hour before each application of 1% Croton oil 2 times a week up to 16 weeks.

**Group 8 (*W. coagulans* fruit Aqueous extract alone)**- *W. coagulans* fruit Aqueous extract was applied at the dose of 1000mg/kg b. wt. on skin 2 times a week up to 16 weeks.

**Group 9 (*W. coagulans* fruit Methanolic extract alone)**- *W. coagulans* fruit methanolic extract was alone applied on skin 2 times a week up to 16 weeks.

### Statistical Analysis

The level of significance was calculated by Student's T- test

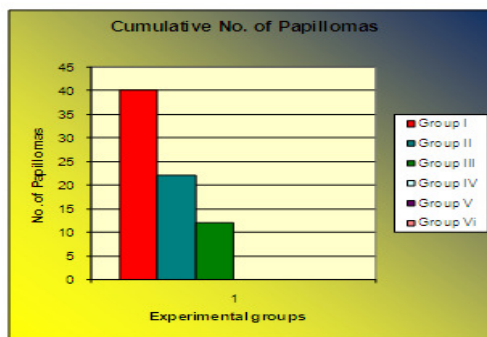
### RESULTS

The present study on skin tumor model revealed out that the single topical application of DMBA followed by Croton oil produced skin papillomas which started appearing from the sixth week onwards. The Tumor incidence in the DMBA+ Croton oil treated mice (Carcinogen control) reached 100% till the end of the experiment (16 weeks). The cumulative no. of papillomas in these mice was recorded as 40. The tumor yield (Average no. of papillomas per mouse) was found to be 100%. Whereas the experimental groups of *W. coagulans* fruit aqueous extract showed 27 cumulative no. of papillomas with tumour incidence of 80% and *W. coagulans* fruit methanolic showed 12 cumulative no. of papillomas with tumor incidence of 50% at the end of experiment. The average latency period (i.e time lag between the application of single topical application of the promoter and appearance of tumors) was also greater in the aqueous and methanolic extract treated mice as compared to untreated group (Table 1 and Graph 1-5). Values were found to be significant at 5% level of significance by Student's 'T' test.

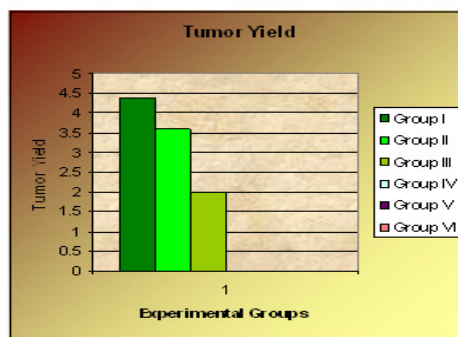
Table 1. Effect of *Withania coagulans* extract on DMBA induced Papillomas in Swiss albino mice.

S.No.	Groups	Treatment	Cumulative no. of papilloma	Tumor Incidence %	Tumor burden	Tumor Yield	Average latent period
1.	Group I	DMBA(104µg/animal + 1%Croton oil (Control group)	40	100%	6.6±0.7	4.4±0.7	33.7±3.5
2.	Group II	DMBA(104µg/animal + 1% croton oil + Aq. (1000mg/kg)	22	80%	4.4±0.2*	3.6±0.8	51.3±4.1
3.	Group III	DMBA (104µg/animal + 1% croton oil + Meth.(1000mg/kg )	12	50%	4.0±0.4	2.0±0.3*	62.5±2.2
4.	Group IV	DMBA alone 104µg/animal	0	0	0	0	0
5.	GroupV	1% Croton oil alone	0	0	0	0	0
6.	GroupVI	Vehicle group Distilled Water	0	0	0	0	0

Mean ± SE , \*denotes statistical significance as compared to DMBA+ Cyclo alone at p<0.05

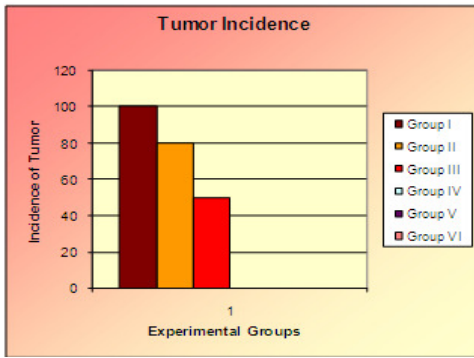


Graph 1.

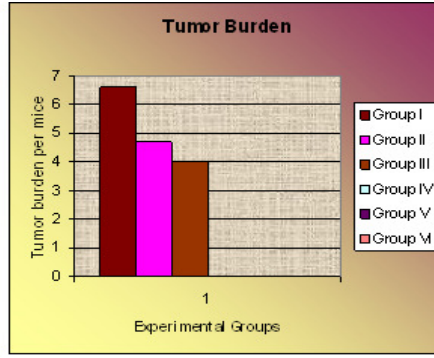


Graph 2

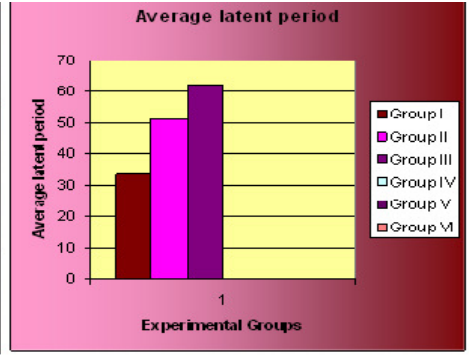
Graph 1. Effect of *W.C* fruits extract on treated mice as compared to the Control Group Cumulative No. of Papillomas in the  
Graph 2. Effect of *W.C* fruit extract on Yield in the treated mice as compared to Control Group



Graph 3.



Graph 4.



Graph 5.

Graph 3. Effects of W.C fruit extract on Tumor Incidence in the treated mice as compared as compared to Control Group

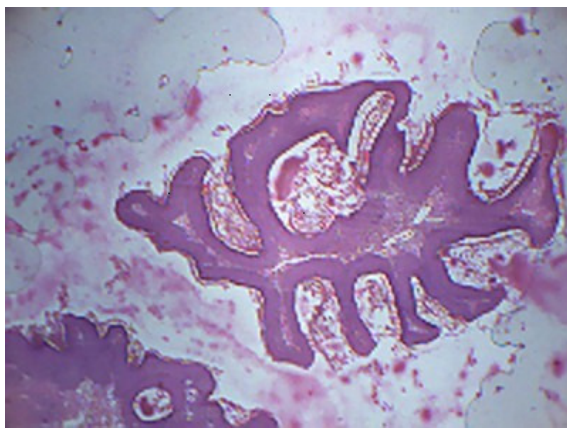
Graph 4. Effects of W.C fruit extract on Tumor burden in the treated mice to Control Group

Graph 5. Effect of W.C fruit extracts on Average latent period of mice in Treated as compared to Control Group

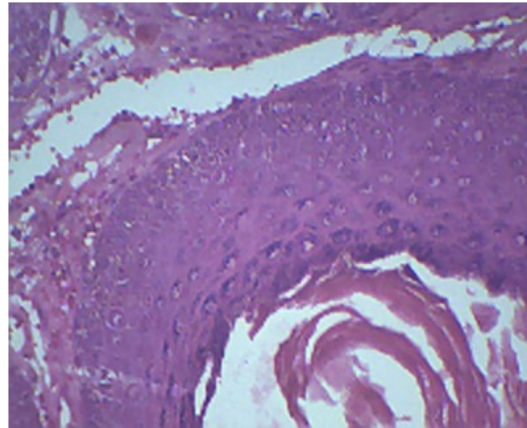
**Histopathological studies of papilloma tumors**

Histological sections in all the groups show marked papillomatosis, hypergranulosis and hyperkeratosis with papillary projections but in the Control group papilloma consisted of fibro vascular core with lump of epithelia showing mild dysplasia, the signs of malignancy were prominent showing keratinous pearl and

full thick dysplasia containing fibro vascular core with lining epithelia. The treated group with Aqueous and Methanolic extract shows finger like papillary projections but none of malignancy. Round nodule with laminated layers called keratinous pearl and papillary projections with slight focal areas of keratin of skin tumor were also observed. The results are shown in Photographs A-D.



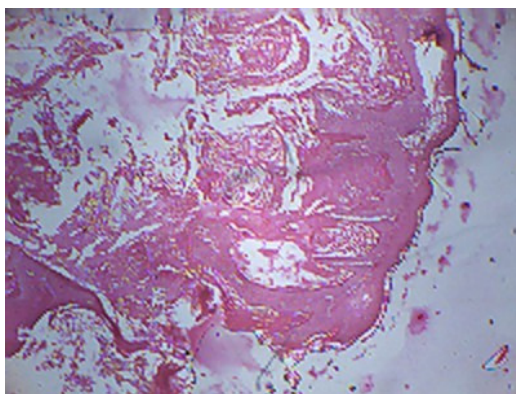
Photograph A



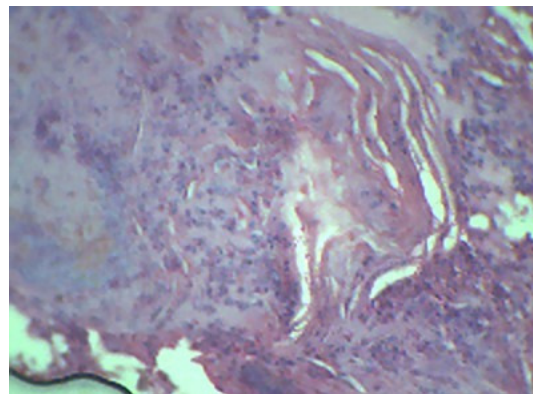
Photograph B

Photograph A. Microphotograph showing papillary projections and Papillary lesions of Skin Tumor (H & E stain Magnification 10×40X)

Photograph B. Microphotograph showing round nodule with laminated layers called Keratinous pearl and papillary projections with focal areas of Keratin of skin tumor (H& E stain, Magnification 10×100X)



Photograph C



Photograph D

Photograph C. Microphotograph showing full thick dysplasia containing fibro vascular core with lining epithelia. (H & E stain Magnification 10×40x)

Photograph D-Microphotograph showing regions of hyperkeratosis and hypergranulosis in focal areas of skin tumor.(H& E stain Magnification 10×100x)

## DISCUSSION

The use of medicinal plants in the management of several ailments dates back to antiquity and is increasing empirically in recent times. The most widely accepted concept of tumorigenesis is a multistage process. The Skin carcinogenesis model in experimental animals has been found useful for investigating the influence of dietary chemo-preventors both mechanistically and operationally [9]. Both extracts of *Withania coagulans* fruit extract as aqueous and methanolic extracts were topically applied on *Swiss albino* mice at concentration of 1000mg/kg. It was observed that both extracts prevent the formation of tumors i.e Cumulative No. of Papillomas and decrease the rate of tumor yield, tumor burden by showing their anti-carcinogenic nature due to presence of withanolide as Active compound. It was reported that application of promoter to the mice skin results in the rapid accumulation of inflammatory cells such as neutrophils and macrophages and an increase in the release of active oxygen species [10-12]. Several studies suggested that compounds possessing anti-inflammatory property inhibit 12-O-tetradecanoyl phorbol-13-acetate induced tumor promotion in mouse skin. Anti-inflammatory steroids drastically inhibit the epidermal DNA synthesis and cellular proliferation induced by phorbol ester tumor promoters, a pre-requisite for tumorigenesis [13]. Though the exact mechanism underlying the anti-inflammatory activity of *Withania coagulans*, has not been ascertained but it may be inferred that due to anti-inflammatory property of *Withania coagulans* might have played a synergistic role in the inhibition of tumorigenesis as observed in the present investigation. Evidence also suggests that tumor promotion may also be due to free radicals (reactive oxygen species), which play an important role in tumor initiation by enhancing or facilitating the metabolic activation and/or initiating the effects of carcinogens [14]. There was a delay in tumor appearance in treated mice with extracts as compared to control which showed appearance of large no. of tumors in short duration of time. Such results show the anti-tumor nature of both extracts. When comparison between both extracts were done than methanolic extract was more effective than aqueous one. That is, methanolic extract prevented the significant number of tumors and also with delay in appearance. The above results suggests that *Withania coagulans* as an herb is very much potent against papilloma tumors.

## REFERENCES

- [1] Anonymous. 1982. *The Wealth of India*, Vol. X pp. 299-306 and 590-581.
- [2] Bown D. 1995. *Encyclopedia of Herbs and their Uses*. Dorling Kindersley, pp.500.
- [3] Budhiraja R.D., S. Sudhir, K.N. Garg and B.C. Arora. 1984. Anti-inflammatory activity of 3 $\beta$ -hydroxy-2, 3-dihydrowithanolide. *F. Planta Med.* 50 (2): 134-136
- [4] Kurup P.A. 1956. Antibiotic principles of leaves of *Withania coagulans*. *Curr. Sci.* 25-57.
- [5] Shohat B., I. Kirson, D. Lavie. 1978. The structure of acnistin B and the immunosuppressive effects of acnistins A, B, and E. *Biomedicine* 28: 18.
- [6] Morse E.C., G. Stoner G. 1996. Cancer chemoprevention: principles and prospects. *Carcinogenesis*. 14: 1737-1746.
- [7] Maiti R.N., M. Manickam, A.B. Ray, R.K. Goel. 1997. Effect of withafastuosin E on gastric mucosal offensive and defensive factors in rats. *Indian J. Exp. Biol.* 35: 751.
- [8] Berenblum I. 1975. *Sequential aspects of chemical carcinogenesis: skin in cancer: A comprehensive treatise*. Plenum Press, New York, 1: 323-344.
- [9] Glotter E. 1980. Distribution of the chemotypes of *Withania somnifera* in some areas of Israel: Feeding studies with *Spodoptera littoralis* larvae and chemical examination of withanolide content. *Experientia*. 36: 998.
- [10] Cerrutti P.A. 1985. Peroxidant states and tumor promotion science (Washington DC). 227: 375-381.
- [11] Copeland E.S. 1983. Free radical in promotion. A Chemical pathology study section workshop. A National Institute of Health Workshop report. *Cancer Research*. 43: 5631-5637.
- [12] Lewis J.G and D.O. Adams. 1987. Early inflammatory changes in the skin of Sencer and C57BL/6 mice following exposure to 12-O-tetradecanoyl phorbol-13-acetate. *Carcinogenesis*. 8: 889-898.
- [13] Aurore V., J.S. Thoma, W. Michael, L.B. Weinstein. 1997. Effects of anti-inflammatory agents on mouse skin tumor promotion, epidermal DNA synthesis, phorbol. ester induced cellular proliferation and production of plasminogen activator. *Cancer Research*. 37: 1530-1536.
- [14] Ather M. 2002. Oxidative stress and experimental Carcinogenesis. *Indian J. Exp. Biol.* 40: 656-667.