



ISSN: 2076-5061

Exploring diverse aspects of celiac disease - A review

Akanksha Chandrakar*

Department of Biotechnology, Singhania University, Pachari Bari, Jhunjhunu-333515, Rajasthan, India

Received: March 29, 2024

Revised: May 24, 2024

Accepted: June 03, 2024

Published: July 01, 2024

*Corresponding author:

Akanksha Chandrakar

E-mail: aakanksha.

chandrakar@gmail.com

ABSTRACT

Celiac disease is a chronic inflammatory disorder triggered by the ingestion of gluten-containing foods in genetically susceptible individuals. This multifactorial disease has both genetic and environmental components, with gluten serving as the environmental trigger and specific genetic variations in the major histocompatibility complex region contributing to the genetic predisposition. Contrary to previous assumptions, celiac disease is not a rare disorder, with a global prevalence estimated at approximately 1%. However, it often remains under-recognized because many affected individuals do not exhibit the classic gastrointestinal symptoms associated with the condition. Instead, they may present with nonspecific manifestations of nutritional deficiencies or may be entirely asymptomatic. Celiac disease is associated with an increased incidence of autoimmune disorders, and its identification in asymptomatic or silent cases is crucial for managing associated conditions and preventing long-term complications such as lymphoma. The relationship between celiac disease and other autoimmune disorders, particularly type 1 diabetes, suggests a potential trigger role for gluten. In this article we review the development of celiac disease, including its types, pathogenesis, clinical features, and associated diseases or complications. We will also discuss available tests, treatments, and preventive approaches related to this subject.

KEYWORDS: Autoimmunity, Celiac disease, Gluten, Inflammation

INTRODUCTION

Celiac disease (CD) is a complex and multigenic disorder. This condition can affect individuals of all ages. People with CD experience an inability to tolerate a protein found in wheat (gliadins), rye (secalins), and barley (hordeins). Proteins found in wheat, rye, and barley share similar structures, they are collectively referred to as gluten. When gluten is consumed, the immune system responds by attacking the lining of the small intestine. This immune response damages the small finger-like projections called villi, which are responsible for absorbing nutrients from food. As a result, individuals with CD may experience malabsorption of essential nutrients such as iron, calcium, vitamins and many more which can affect a broad range of conditions that can impact various aspects of the body or multiple organ systems. CD is estimated to impact around 1% of the global population (Roshan *et al.*, 2011; Kochhar *et al.*, 2016).

The symptoms of CD can vary greatly, and some individuals may not experience any symptoms at all. Common symptoms include diarrhea, bloating, abdominal pain, fatigue, and weight loss. In children, the disease can lead to delayed growth and development. If left untreated, CD can give rise to serious health complications including anemia, osteoporosis, and certain types

of cancer (Swinson *et al.*, 1983; Logan *et al.*, 1989). Nutrient deficiencies caused by the damage to the small intestine may make individuals with CD more susceptible to infections and other diseases, as the immune system relies on nutrients such as iron and vitamins to function properly (Dieterich *et al.*, 1997; Fasano & Catassi, 2001).

CD is primarily a genetic disorder, meaning that it arises from specific genes inherited from parents. These genes are located on chromosome 6 and are known as human leukocyte antigen (HLA) genes. Particularly, the HLA-DQ2 and HLA-DQ8 genes are strongly associated with CD (Schuppan, 2000; Pozo-Rubio *et al.*, 2012). These genes produce proteins that assist the immune system in distinguishing between “self” and “non-self” cells, identifying foreign invaders like bacteria or viruses. In people with CD, the proteins produced by the HLA-DQ2 or HLA-DQ8 genes are more likely to recognize and respond to gluten as if it were a foreign invader. However, it’s important to note that not all individuals carrying these genes will develop CD. In addition to genetic factors, environmental influences may also contribute to the development of CD (van Heel *et al.*, 2007; Lionetti & Catassi, 2011). Factors such as the timing of gluten introduction during infancy, breastfeeding, viral infections, and the composition of the gut microbiome may impact an individual’s risk of developing the disease. Gluten

Copyright: © The authors. This article is open access and licensed under the terms of the Creative Commons Attribution License (<http://creativecommons.org/licenses/by/4.0/>) which permits unrestricted, use, distribution and reproduction in any medium, or format for any purpose, even commercially provided the work is properly cited. Attribution — You must give appropriate credit, provide a link to the license, and indicate if changes were made.

exposure, specifically the amount and duration, can affect the severity and progression of the condition. CD can develop at any age, but it is most commonly diagnosed in childhood or early adulthood (Roehr *et al.*, 2004; Cosnes *et al.*, 2008; Narula *et al.*, 2021). Individuals with autoimmune disorders, like type 1 diabetes, autoimmune thyroid disease, or autoimmune liver disease, have an increased risk of developing CD. The gut microbiome, consisting of microorganisms in the gut, can influence the immune system's response to gluten and thereby affect the development of CD (de Sousa Moraes *et al.*, 2014). Antibiotic use during infancy may also impact the likelihood of developing CD (Guidetti *et al.*, 2001; Ouaka-Kchaou *et al.*, 2008). It's crucial to recognize that while these factors may heighten the risk of developing CD, not all individuals with these risk factors will develop the condition. Furthermore, some individuals may develop CD without any known risk factors.

What is Gluten?

Gluten is found in grains from the family Gramineae, specifically in the subfamily Festucoideae, tribe Triticeae, and subtypes Triticinae and Hordeinae. The most commonly consumed grains that contain gluten are wheat (genus *Triticum*), rye (genus *Secale*), and barley (genus *Hordeum*) (Kasarda *et al.*, 1984). Some other grains such as spelt, kamut, triticale, and farro also contain gluten (Wolters & Wijmenga, 2008; Lionetti & Catassi, 2011). Figure 1 explains taxonomic groupings and relation of major cereal grains.

Gluten has specific names depending on the cereal it comes from, such as gliadin in wheat, hordein in barley, and secalin in rye. Despite their different names, these proteins share similar structures and properties. Collectively, they are referred to as gluten (Fernández *et al.*, 2010; de Sousa Moraes *et al.*, 2014). Gluten proteins can be divided into two main groups: gliadin and glutenin. Gliadins are soluble proteins, meaning they can dissolve in water, they are the smaller of the two proteins and are mainly responsible for triggering the immune response in individuals with CD or gluten sensitivity (Shan *et al.*, 2002; Green & Cellier, 2007). Glutenins, on the other hand, are insoluble proteins that form a complex network when mixed with water and provide elasticity and strength to the gluten

structure, which allows bread dough to stretch and rise during baking. Both gliadins and glutenins are characterized by high levels of the amino acids glutamine and proline (Wieser, 2007).

Pathogenesis of Celiac Disease

In CD, the immune system's response to gluten involves the production of antibodies against gluten. These antibodies can be found in the blood as well as in other tissues, such as the skin and the small intestine. Unfortunately, these antibodies can also attack the body's tissues, leading to the development of other autoimmune disorders.

The small intestine's lamina propria contains various immune cells, including T cells, B cells, macrophages, and dendritic cells. These immune cells play crucial roles in both innate and adaptive immune responses. They work together to monitor the intestinal environment for potential pathogens and respond to foreign substances that may be present. In CD, the lamina propria experiences inflammation characterized by an influx of lymphocytes and plasma cells. This inflammation is accompanied by increased production of cytokines, such as interferon gamma and interleukin-15, resulting in damage to the intestinal lining (Maiuri *et al.*, 2000; Fehniger & Caligiuri, 2001; Lionetti & Catassi, 2011).

T cells play a key role in the pathogenesis of CD. When gluten is ingested in the small intestine, it is broken down into gliadin and glutenin. The enzyme tissue transglutaminase (tTG) modifies the gliadin peptides through deamidation, a process that changes their structure. This modification allows the gliadin peptides to bind more strongly to HLA molecules, which are responsible for presenting antigens to T cells. In individuals with CD, T cells recognize the modified gliadin peptides as foreign, triggering an immune response. The immune response involves the activation of T cells, which release cytokines. Cytokines are chemical messengers that attract other immune cells to the site of the reaction. The activated T cells also proliferate and differentiate into effector cells, producing different types of interferons, cytokines, and tumor necrosis factor (Schuppan *et al.*, 2009; Pender *et al.*, 1997). These substances contribute to inflammation and tissue damage.

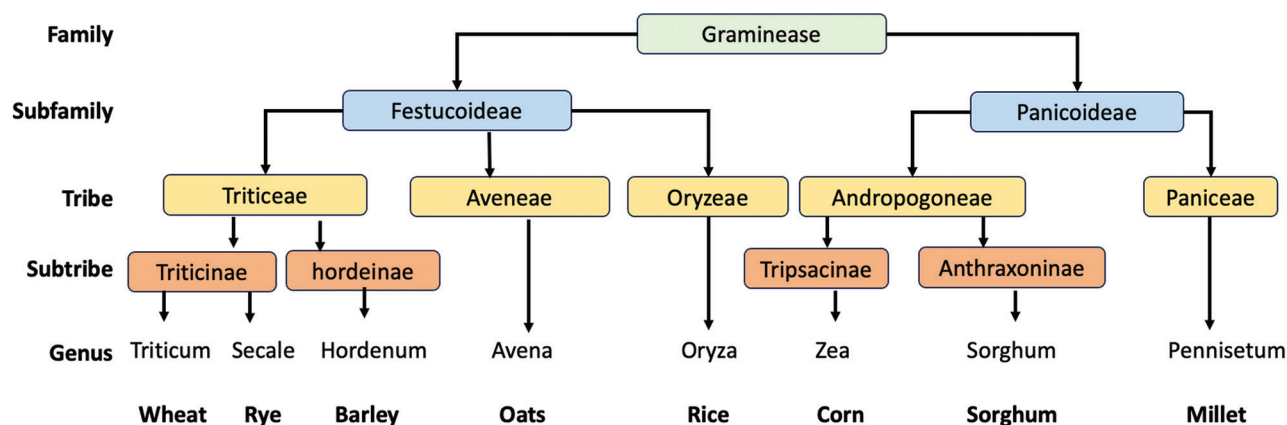


Figure 1: Taxonomic Groupings and Relation of Major Cereal Grains

B cells are stimulated by the T cell activation to produce antibodies against gliadin. These antibodies, including anti-gliadin, anti-endomysial, and tTG antibodies, are characteristic markers of CD (Dieterich *et al.*, 1997; Di Sabatino & Corazza, 2009). These antibodies can further contribute to tissue damage by forming immune complexes that deposit in the small intestine. Additionally, these autoantibodies can be used for diagnostic purposes and may play a role in the development of the disease. Pathogenesis of CD is explained in Figure 2.

In addition to triggering the adaptive immune response, gluten can also activate the innate immune response. Immune cells, such as natural killer cells, macrophages, and eosinophils, present in the lining of the small intestine, also contribute to the immune response. They release additional cytokines and chemical mediators that further promote inflammation and tissue damage. Over time, the immune response in CD leads to villous atrophy and structural changes in the small intestine. These changes impair nutrient absorption and exacerbate symptoms. It is important to note that genetic factors, particularly the presence of specific HLA-DQ molecules, known as HLA-DQ2 and HLA-DQ8,

play a significant role in the development of CD. However, not all individuals with these genetic susceptibilities develop CD, suggesting that other factors are involved. Further research is needed to understand how genes interact with other factors to contribute to the development of this complex disorder.

Types of Celiac Disease

Celiac disease can be classified into different subgroups based on the variety of symptoms exhibited by individuals and the results obtained from laboratory findings as explain in Table 1.

Classical (typical form) CD

The classical form of CD usually develops between 6 and 24 months of age. It is characterized by villous atrophy and symptoms related to intestinal malabsorption. Common findings in this form of CD include chronic diarrhea, anemia, impaired growth, abnormal stools, abdominal distension, muscle wasting, hypotonia, poor appetite, and unhappy behavior (Dewar & Ciclitira, 2005).

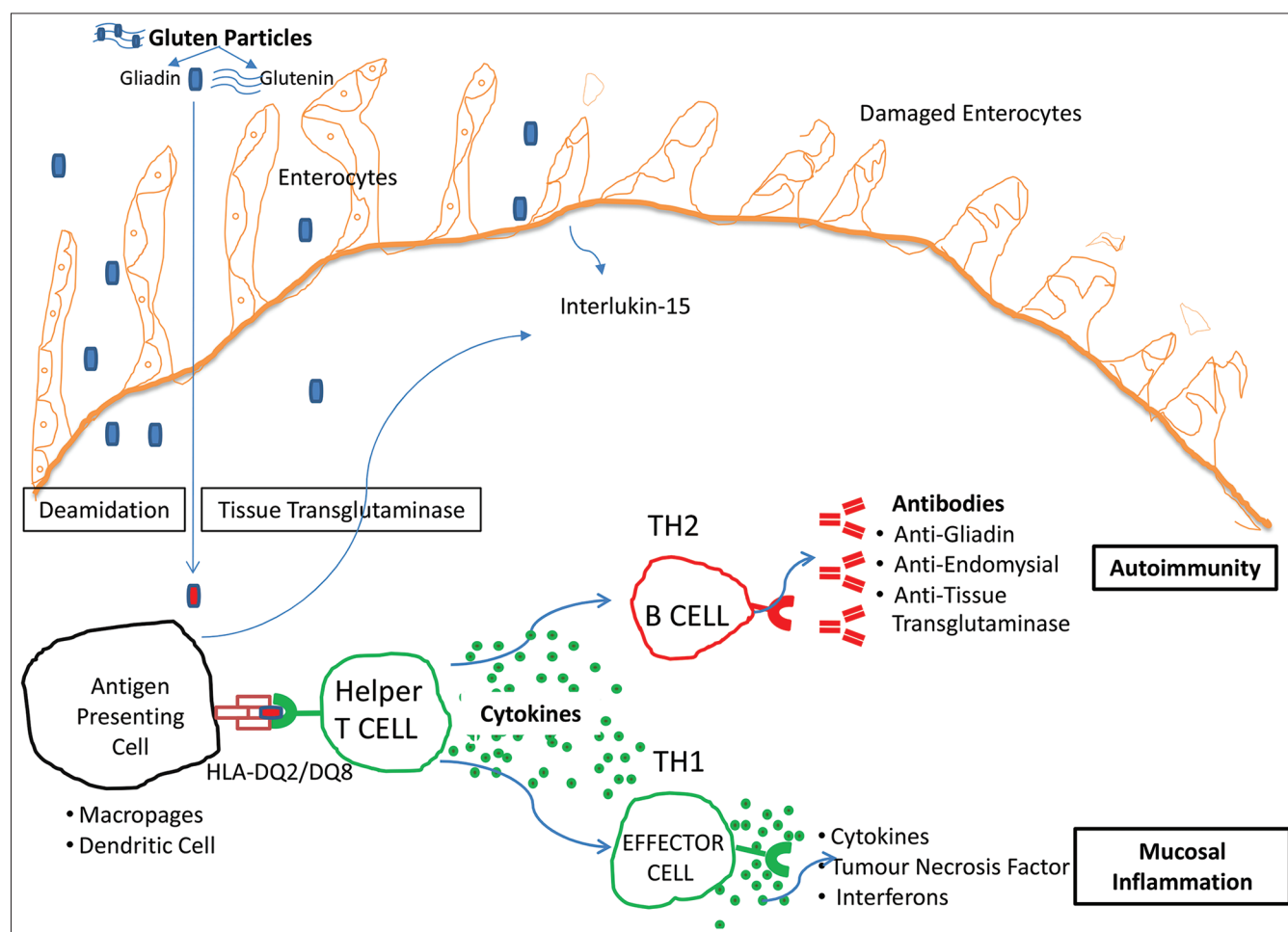


Figure 2: Pathogenesis of Celiac Disease- Undigested gluten peptides to reach the lamina propria. There tissue transglutaminase modifies the gluten peptides and presented to HLA in antigen-presenting cells leading to specifically B cell and Effector cell immune responses. These immune responses lead to the production of antibodies and inflammation in the mucosal lining of the intestine

Table 1: Types of Celiac Disease and Their Respective Symptoms

Type of CD	Typical Symptoms	Atypical or Extraintestinal Symptoms	Other Characteristics
Classical CD	Diarrhea, Abdominal pain, Bloating, Weight loss, Fatigue	Nutritional deficiencies (e.g. iron, calcium, vitamin D, B12)	Most common type
Non-classical CD	Anemia, Osteoporosis, Neuropathy, Skin rash,	Headaches or migraines, depression or anxiety, infertility	Symptoms may not involve the gastrointestinal tract
Refractory CD	Persistent gastrointestinal symptoms, Weight loss, Malnutrition	Nutritional deficiencies, abdominal distention, anemia	Rare and severe, may require more aggressive treatment
Asymptomatic or silent CD	No apparent symptoms, but Iron Deficiency, Behavioral Disturbances, Impaired physical fitness, and reduced bone mineral density	Positive CD serology, intestinal damage on biopsy	May be discovered incidentally during screening or biopsy
Potential CD	No symptoms or Mild gastrointestinal symptoms	Positive CD serology, no intestinal damage on biopsy	May require monitoring or a gluten-free diet

Non-classical (Atypical form) CD

Non-classical forms of CD are characterized by a prevalence of extra-intestinal symptoms, often with few or no gastrointestinal symptoms. They are commonly seen in older children and adults. The symptoms and manifestations of atypical CD can vary widely and affect various organ systems. Some common features include recurrent abdominal pain, nausea, vomiting, bloating, dental enamel defects, recurrent aphthous stomatitis, isolated increase in liver enzymes, anemia (particularly iron deficiency anemia), dermatitis herpetiformis (a blistering skin disease), short stature, arthritis and arthralgia, chronic hepatitis and elevated liver enzymes, osteoporosis, neurological problems, delayed onset of puberty, recurrent miscarriage, reduced fertility, and reduced bone mineral density (Lionetti & Catassi, 2011; Parzanese *et al.*, 2017).

Refractory CD

The refractory form of CD refers to a condition where individuals continue to experience malabsorptive symptoms and have persistent villous atrophy in the small intestine despite following a strict gluten-free diet for at least one year. It is estimated that approximately 5% to 30% of individuals with refractory CD do not respond to the gluten-free diet (Green & Cellier, 2007; Kochhar *et al.*, 2016), while others may initially respond but later experience a recurrence of symptoms and intestinal damage. There are two recognized subtypes of refractory CD based on the characteristics of intraepithelial lymphocytes in the small intestine.

Type 1 refractory CD, is characterized by a normal count of intraepithelial lymphocytes. In this subtype, although the symptoms and villous atrophy persist, there are no abnormal cell populations observed. Type 1 refractory CD can often be managed with medications and other treatment approaches (Freeman *et al.*, 2011; Lähdeaho *et al.*, 2014).

Type 2 refractory CD, on the other hand, involves the presence of aberrant or abnormal intraepithelial lymphocytes in the small intestine. In celiac disease, T-cells react to gluten, causing intestinal damage. With a gluten-free diet, this damage usually heals. In Type 2 refractory CD, T-cells are activated without

gluten, and intestinal damage persists even without gluten consumption. This subtype carries a higher risk of developing into a type of lymphoma, a cancer of the lymphatic system (Cellier *et al.*, 2000; Jabri *et al.*, 2005).

Asymptomatic (silent form) CD

This type refers to a form of the condition where individuals do not exhibit the typical symptoms associated with celiac disease such as diarrhea, abdominal pain, and weight loss, but still have the characteristic small intestine damage when gluten is consumed. They are still at risk for the long-term complications of CD, including nutritional deficiencies, osteoporosis, and an increased risk of certain autoimmune conditions and malignancies.

Potential CD

Potential CD refers to individuals who have not been diagnosed with CD but display certain indications that suggest a potential risk for developing the condition. These individuals typically have the appropriate genetic background associated with CD, specifically the presence of HLA genotypes HLA-DQ2 and/or HLA-DQ8, which are known to be associated with increased susceptibility to CD (Parzanese *et al.*, 2017). In addition to the genetic markers, individuals with potential CD also exhibit positive serology. This means that they have detectable antibodies in their blood that are commonly associated with CD, such as anti-tissue transglutaminase antibodies and/or anti-endomysial antibodies (EMA) (Di Sabatino & Corazza, 2009). The presence of these antibody tests is used to screen for CD and can indicate an immune response to gluten. However, despite having a genetic predisposition and positive serology, the histological examination of their intestinal mucosa appears normal or only mildly abnormal. The presence of normal or mildly abnormal histology means that the microscopic examination of the intestinal tissue does not show the characteristic damage associated with CD, such as villous atrophy or significant inflammation. Individuals with potential CD may or may not experience symptoms related to gluten consumption. Some may have gastrointestinal symptoms, while others may be asymptomatic (Lionetti & Catassi, 2011).

Complications and Related Diseases Associated with Celiac Disease

CD is an autoimmune disorder that affects the small intestine. However, several other conditions are commonly associated with CD. One condition that is closely related to CD is dermatitis herpetiformis. Dermatitis herpetiformis is a type of blistering skin disease characterized by the presence of immunoglobulin A (IgA) deposits in the skin (Fry, 1995; Zane *et al.*, 1996). It is now considered a variant of CD. While dermatitis herpetiformis does not typically cause intestinal symptoms, most patients with this skin condition have some degree of enteropathy (inflammation of the small intestine) when a biopsy is taken (Jaskowski *et al.*, 2009). The rash associated with dermatitis herpetiformis is often found on the elbows, knees, and buttocks.

CD and type 1 diabetes are closely associated with autoimmune disorders that affect the pancreas and cause the body to produce little or no insulin (Kumar *et al.*, 2001; Mahmud *et al.*, 2005; Parzanese *et al.*, 2017). Research has shown that individuals with type 1 diabetes have a 5- to 10-fold higher risk of developing CD compared to the general population, especially in children. This increased risk is partly due to shared genetic factors, particularly the HLA genes. Approximately 5% to 10% of individuals with type 1 diabetes have CD-related antibodies, and up to 75% of them show abnormalities in the small intestine (Nepom & Kwok, 1998; Hummel *et al.*, 2000). On the other hand, individuals with CD also have an increased risk of developing type 1 diabetes. The association between these two conditions is well-established, and individuals with CD need to be aware of the heightened risk of developing type 1 diabetes.

The relationship between CD and osteoporosis is closely linked. Osteoporosis and its precursor, osteopenia, are commonly seen in individuals with CD due to malabsorption of vitamin D (Mora *et al.*, 1999; Fouda *et al.*, 2012). Approximately two-thirds of patients with CD may develop osteoporosis or osteopenia (Meyer *et al.*, 2001). CD affects the small intestine, leading to damage to the intestinal lining and impairing the absorption of important nutrients, including vitamin D. Vitamin D plays a crucial role in maintaining bone health by promoting calcium absorption and regulating bone metabolism. Deficiency in vitamin D can lead to decreased calcium absorption and impaired bone mineralization, contributing to the development of osteoporosis (Sategna-Guidetti *et al.*, 2000).

Additionally, CD can lead to iron deficiency anemia, a condition in which there are too few red blood cells in the body, which can lead to fatigue, weakness, and other symptoms. Iron deficiency anemia is a common symptom of CD. It may be the only sign of the disorder and is often unresponsive to oral iron supplements.

CD and thyroid disorders, particularly autoimmune thyroid diseases like Hashimoto's thyroiditis and Graves' disease, are associated with each other (Stazi & Trinti, 2010; van der Pals *et al.*, 2014). CD involves the immune system mistakenly attacking the small intestine in response to gluten, while autoimmune thyroid diseases involve the immune system attacking the thyroid gland.

Individuals with CD have a higher likelihood of developing thyroid disorders, and it is recommended to screen both CD patients for thyroid abnormalities and vice versa. Genetic factors, specifically HLA-DQ2 haplotypes, are shared between CD and Hashimoto's thyroiditis (Nepom & Kwok, 1998; Kumar *et al.*, 2001; Bluestone *et al.*, 2015). Selenium deficiency resulting from abnormal absorption in CD may contribute to thyroid and intestinal damage, as the thyroid is sensitive to selenium deficiency. Monitoring growth, pubertal status, and CD markers is important in individuals with autoimmune thyroid disease. Screening for thyroid abnormalities is suggested in some cases for individuals with CD.

Liver abnormalities are a common occurrence in individuals with CD. When people are diagnosed with CD and show typical symptoms, around 40% of adults and 54% of children have elevated levels of liver enzymes, a condition known as hypertransaminasemia. Conversely, the CD is found in about 9% of patients who have chronic unexplained hypertransaminasemia (Rubio-Tapia & Murray, 2007). The mechanism behind liver damage in CD is believed to involve the entry of toxins, inflammatory molecules, and antigens into the portal circulation. It has been suggested that individuals with persistent hypertransaminasemia of unknown cause should undergo serological screening for CD. Additionally, it is important to exclude gluten-related liver damage in patients with autoimmune liver disorders or severe liver diseases of unknown etiology, as well as in those who are being considered for liver transplantation. Prolonged exposure to gluten in individuals with undiagnosed CD can lead to chronic hepatitis and liver cirrhosis. Therefore, it is crucial to consider CD as a potential underlying cause of liver abnormalities, and screening for CD should be conducted in relevant patient populations.

Individuals with CD have an increased risk of developing certain malignancies particularly those of the gastrointestinal tract (Swinson *et al.*, 1983; Summaries for patients, 2013). The most common malignancies associated with CD are enteropathy-associated T-cell lymphoma, a type of non-Hodgkin lymphoma, and small bowel adenocarcinoma (Elfström *et al.*, 2012). Other malignancies that have been reported to be more frequent in individuals with CD include esophageal cancer, gastric cancer, pancreatic cancer, thyroid cancer, malignant melanoma and hepatocellular carcinoma (Lebwohl *et al.*, 2014). The risk of developing malignancies in individuals with CD is thought to be related to chronic inflammation and immune dysfunction associated with the disease. Therefore, individuals with CD need to receive appropriate medical care and regular monitoring for the development of malignancies. Compliance with a strict gluten-free diet has been shown to reduce the risk of malignancies in individuals with CD.

There is growing evidence suggesting a potential association between CD and various neurological disorders. However, the available data on this topic are still limited. One neurological disorder that has been linked to CD is ataxia, which is characterized by a loss of coordination (Pellecchia *et al.*, 1999). Additionally, epilepsy is the most common neurological condition among individuals with CD, with a prevalence

ranging from 1.2% to 5%. The clinical presentation of epilepsy in association with CD can vary, ranging from focal to generalized seizures, with different outcomes and responses to a gluten-free diet. In some cases, a specific syndrome called CD, epilepsy, and occipital calcifications have been described. It is believed that the HLA genotype associated with CD also predisposes individuals to occipital calcifications (Gobbi, 2005). CD can also manifest with other neurological symptoms such as headaches, peripheral neuropathy (nerve damage affecting the extremities), and behavioral changes. It has been observed that gluten sensitivity is common among patients with neurological disorders of unknown cause.

Lactose intolerance: CD can damage the lining of the small intestine, which can make it more difficult for the body to digest lactose, a sugar found in dairy products. Short stature is a symptom of CD that is common in some older children and adolescents. Up to 10% of those with idiopathic short stature may have CD (Groll *et al.*, 1980; Cacciari *et al.*, 1983). Patients with this symptom may have significantly impaired bone age and growth velocity. Some may also have reduced growth hormone production, which typically returns to normal after they adopt a GFD. Dental enamel hypoplasia is a condition in which the teeth have less enamel than normal. It is found in up to 30% of untreated CD patients (Swinson *et al.*, 1983).

Arthritis and arthralgia are joint symptoms that are reported in 1.5% to 7.5% of patients with rheumatoid arthritis (George *et al.*, 1996; Mahadev *et al.*, 2018). In some cases, these symptoms are the only sign of CD, and they improve when a GFD is adopted. Other extragastrointestinal symptoms of CD include delayed onset of puberty, recurrent abortions, and reduced fertility (Farthing *et al.*, 1983). Women with CD have a higher risk of abortion than healthy individuals. If left untreated, CD can lead to a range of complications and health problems, including malnutrition, anemia, infertility and miscarriage, intestinal cancer, neurological problems, and other autoimmune disorders. Compliance with a strict gluten-free diet has been shown to reduce the risk of malignancies in individuals with CD. However, it's important to note that not everyone with CD will develop these conditions, and the severity and presentation of symptoms can vary widely between individuals.

Diagnostic Methods for Celiac Disease

Serological tests

It plays a crucial role in the diagnosis of CD by examining the presence of specific antibodies in a patient's blood. These tests help identify individuals who may have an immune response to gluten proteins, indicating the likelihood of CD. Here are some key points regarding serological tests for CD:

IgA anti-tissue transglutaminase antibodies

This test is considered the most effective serological test for CD. It detects the presence of IgA antibodies against tTG using an

enzyme-linked immunosorbent assay (ELISA). Elevated levels of tTG antibodies are highly indicative of CD (Fasano, 1999; Sblattero *et al.*, 2000).

IgA anti-endomysial antibodies (IgA EMA)

In cases where tTG antibodies are positive, IgA EMA antibodies are used as a confirmatory test. IgA EMA antibodies are specific to the endomysium, a connective tissue component, and their presence further supports the diagnosis of CD (Green & Cellier, 2007; Lionetti & Catassi, 2011; Parzanese *et al.*, 2017).

tTG-IgG testing

When individuals have a deficiency in IgA antibodies, which can occur in a small percentage of CD patients, IgA-based tests may yield false negative results. In such cases, tTG-IgG testing is recommended to ensure accurate diagnosis. This test detects Immunoglobulin G (IgG) antibodies against tissue transglutaminase (Kumar *et al.*, 2001).

Anti-gliadin antibodies

Traditional anti-gliadin antibodies are no longer recommended as their accuracy is relatively low, except in younger children. They have been replaced by more reliable tests such as IgA tTG antibodies and IgA EMA (Dieterich *et al.*, 1997; Rubio-Tapia *et al.*, 2013).

Deamidated gliadin peptides

Deamidated gliadin peptides are a newer type of immunoassay that has replaced the use of anti-gliadin antibodies. These tests have shown improved accuracy and sensitivity in detecting CD (Kumar *et al.*, 2001; Parzanese *et al.*, 2017).

It's important to note that serological tests are usually performed in conjunction with other diagnostic evaluations, such as genetic testing and duodenal biopsy, to establish a definitive diagnosis of CD.

Biopsy

The most reliable method for diagnosing CD is through a duodenal biopsy. This procedure involves taking a small tissue sample from the lining of the duodenum, which is the first part of the small intestine. The tissue sample is then examined under a microscope to assess the histologic features, providing important diagnostic information. During the histologic examination, the pathologist looks for specific changes that are indicative of CD. These changes may include:

Flattening of Intestinal Villi: In a healthy intestine, the surface area for nutrient absorption is increased by finger-like projections called villi. In CD, the villi may appear flattened or blunted, reducing the absorptive surface area. This flattening is one of the key features observed in the biopsy (Villanacci *et al.*, 2011).

Crypt Hyperplasia: Crypts are small, tube-like structures located between the villi. In CD, the crypts may appear enlarged or hyperplastic. This change is often seen in conjunction with villous flattening (Fouda *et al.*, 2012).

Infiltration of Lymphocytes: The lamina propria, a layer of tissue beneath the surface epithelium, may show an increased number of lymphocytes. Lymphocytes are a type of white blood cell involved in the immune response. Their presence in the lamina propria is a characteristic finding in CD (Kochhar *et al.*, 2016).

By examining these histologic features, a pathologist can confirm or rule out a diagnosis of CD. It's important to note that the duodenal biopsy is typically performed after positive serologic testing for CD, which includes blood tests for antibodies associated with the disease. The combination of serologic testing and histologic examination of the biopsy provides a more definitive diagnosis. It's worth mentioning that the biopsy findings can vary in their severity and extent among different individuals. Some individuals may show severe damage to the villi, while others may have milder changes. The degree of histologic abnormalities can also correlate with the duration and severity of the disease.

Genetic testing

For HLA-DQ2 and HLA-DQ8 is a valuable tool in the diagnosis of CD, especially in cases where there is discordance between serologic tests and histopathological findings. If one type of test is positive (either serologic or histologic) and the other is negative, genetic testing can help clarify the diagnosis. A negative genetic test for HLA-DQ2 and HLA-DQ8 makes CD highly unlikely, as these genetic markers are present in the majority of individuals with the condition (Hadithi *et al.*, 2007; Catassi & Fasano, 2010). HLA testing can also be useful for ruling out CD in family members of celiac patients. Genetic testing is particularly useful in certain scenarios. For example, if a patient is already following a gluten-free diet before seeking medical evaluation and has not undergone prior testing for CD, a negative genetic test for HLA-DQ2 and HLA-DQ8 suggests that CD is unlikely to be the cause of their symptoms. However, it's important to note that a positive genetic test alone is not sufficient to diagnose CD definitively. It indicates the presence of genetic susceptibility to the condition but does not differentiate between CD and non-celiac gluten sensitivity. If the genetic test is positive, further testing is necessary to confirm the diagnosis. This typically involves a gluten challenge.

Gluten challenge

It is a diagnostic procedure that involves reintroducing gluten into the diet of individuals suspected of having CD. It is conducted when serologic and genetic testing is inconclusive and aims to assess the response to gluten consumption and the recurrence of symptoms. The duration of the gluten challenge may vary, and it should be performed under the supervision of a healthcare professional. During a gluten challenge, the patient is instructed to consume foods that contain gluten, such as wheat, barley, and rye, for a specific period. Ideally, the

duration of the gluten challenge is 8 weeks, as this allows for a sufficient amount of time to assess the response to gluten. However, in cases where longer consumption of gluten is not tolerable for the patient, a minimum period of 2 weeks may be considered. The purpose of the gluten challenge is to observe if the reintroduction of gluten triggers the return of symptoms associated with CD. If the patient experiences a recurrence of symptoms, it provides supportive evidence for a diagnosis of CD.

Stool tests

These tests can detect elevated levels of fat in the stool, which can be a sign of malabsorption due to CD.

Imaging tests

Imaging tests such as a small bowel series or abdominal CT scan may be used to look for signs of intestinal damage or inflammation.

Endoscopy with capsule endoscopy

This test involves swallowing a small capsule that contains a camera, which takes pictures of the small intestine as it passes through the digestive tract. This can be useful in detecting areas of damage or inflammation that may be missed by traditional endoscopy.

Individuals should not start a gluten-free diet before being tested for CD.

Doing so can lead to false negative results and make it more difficult to diagnose the condition.

Treatments for Celiac disease

The primary treatment for CD is a gluten-free diet. This means avoiding all foods and products that contain gluten, which is a protein found in wheat, barley, and rye, as well as any products made with these grains. When individuals with CD follow a gluten-free diet, they typically experience significant improvements in their symptoms. Here are the key points regarding the benefits of a gluten-free diet: a) Abdominal Pain Improvement: Many patients with CD experience abdominal pain as one of their symptoms. After starting a gluten-free diet, most patients report a noticeable improvement in abdominal pain within just a few days. This rapid response is encouraging and reinforces the importance of dietary management (Murray *et al.*, 2004). b) Diarrhea Improvement: Diarrhea is another common symptom of CD caused by the malabsorption of nutrients in the small intestine. With the elimination of gluten from the diet, the intestinal lining begins to heal, and the body becomes better able to absorb nutrients properly. As a result, diarrhea typically improves within a few weeks of starting a gluten-free diet. It's worth noting that the timeline for symptom improvement may vary among individuals. While some people may experience rapid relief, others may require more time for

their symptoms to subside. The extent of intestinal damage and individual differences can influence the rate of improvement.

Adhering to a gluten-free diet requires strict avoidance of gluten-containing foods and ingredients. This involves careful reading of food labels, selecting naturally gluten-free foods, and being aware of hidden sources of gluten in processed foods and cross-contamination risks in food preparation. It is important to work with a healthcare professional and a registered dietitian to develop a well-balanced gluten-free diet that meets all the nutritional needs. This can involve replacing gluten-containing products with gluten-free alternatives. There are now many gluten-free alternatives available for individuals with CD, including gluten-free bread, pasta, flour, and baked goods. It is important to choose products that are fortified with key nutrients and that are free from other potential allergens or intolerances. In addition to a gluten-free diet, the healthcare provider may also recommend vitamin and mineral supplements, such as iron, calcium, vitamin D, vitamin B12, and folate, to address any deficiencies that may have developed due to malabsorption (Hopman *et al.*, 2006; Freeman *et al.*, 2011). It's important to note that strict adherence to a gluten-free diet is necessary to manage CD and prevent complications. Even small amounts of gluten can cause damage to the small intestine and lead to symptoms and long-term complications. In rare cases where a strict gluten-free diet is not effective in managing symptoms or complications, other treatments such as medications or additional interventions may be recommended by a healthcare professional. The examples of gluten containing and gluten free products are listed in Table 2.

The gut microbiome, which refers to the complex community of microorganisms that inhabit the digestive tract, may play an important role in the recovery and management of CD. Researches (Turnbaugh *et al.*, 2009; Kau *et al.*, 2011; de Sousa Moraes *et al.*, 2014) have shown that individuals with CD may have an altered gut microbiome compared to those without the condition. Specifically, there may be a reduction

in beneficial bacteria and an increase in potentially harmful bacteria in the gut. Studies have also suggested that changes in the gut microbiome may contribute to the development and progression of CD, as well as associated conditions such as irritable bowel syndrome. The gut microbiota may play a role in the pathogenesis and management of CD. gut microbiota can modulate the immune response to gluten and influence the severity of CD. Certain strains of bacteria have been shown to degrade gluten peptides, potentially reducing the immunogenicity of gluten, and decreasing the inflammatory response in the gut (Sommer *et al.*, 1987; Wu *et al.*, 2010). The probiotic VSL#3 appears to have a protective effect by mitigating the abnormal response to gliadin in celiac disease. Gliadins treated with the probiotic VSL#3 were found to decrease the activation of zonulin release, cytoskeleton reorganization, and intestinal permeability compared to non-hydrolyzed wheat gliadins. Probiotic bacteria in VSL#3 enhanced tight junctions in intestinal cells, preventing the dissolution of tight junctions and redistribution of zonulin-1, which are associated with increased permeability. VSL#3 preparation influences T cell activation and the immune response in the small intestine, reducing the infiltration of CD3+ intraepithelial lymphocytes. Modifying the gut microbiome through interventions such as probiotics, prebiotics, and dietary changes may have potential benefits in the management of CD. Probiotics may help to restore a healthy balance of gut bacteria, while prebiotics may promote the growth of beneficial bacteria (De Angelis *et al.*, 2006; Lindfors *et al.*, 2008).

CD is currently treated with a life-long gluten-free diet, which usually results in clinical improvement within a few weeks, and the mucosal damage recovers in 1-2 years (Guidetti *et al.*, 2001; Cosnes *et al.*, 2008). However, the gluten-free diet may be difficult to follow, and even products specifically targeted to dietary treatment of CD may contain tiny amounts of gluten proteins. Refractory CD is a form of the disease that may require corticosteroids and other immunosuppressant drugs, which can improve clinical symptoms in most patients, but not in all cases

Table 2: Examples of Gluten-Containing and Gluten-Free Products

Food and food products that contain gluten	Foods that are naturally gluten-free
Wheat (including spelt, kamut, and farro)	Fruits and vegetables
Barley	Fresh meats, fish, and poultry (without added marinades or seasonings)
Rye	Eggs
Triticale (combination of wheat and rye)	Dairy products (without added flavors or thickeners)
Semolina	Beans and legumes (chickpeas, lentils, kidney beans, etc.)
Farina	Nuts and seeds (almonds, walnuts, sunflower seeds, etc.)
Bread, pasta, and baked goods made from wheat flour	Gluten-free grains (rice, amaranth, sorghum millet quinoa, etc.)
Beer and other malt beverages	Gluten-free flours and starches (potato starch, tapioca starch, cornstarch, etc.)
Cereals and granolas that contain wheat, barley, or rye	Gluten-free pasta (made from rice, corn, or quinoa)
Processed foods that contain wheat, barley, or rye as an ingredient, such as soups, sauces, and salad dressings	Gluten-free breads and baked goods (made from gluten-free flours)
Croutons and breadcrumbs	
Couscous	
Bulgur	
Seitan (wheat meat)	
Soy sauce and other sauces that contain wheat	
Some types of vinegar, such as malt vinegar	
Some types of food starch, such as modified food starch	
Some types of flavorings and spices, such as seasoning mixes and spice blends that contain wheat, barley, or rye	

(Logan *et al.*, 1983; Green & Cellier, 2007). Gluten-degrading enzymes have been proposed to accelerate gluten digestion in the gastrointestinal tract and destroy T-cell epitopes, and two drug candidates, ALV003 and AN-PEP, are undergoing clinical trials (Fasano *et al.*, 2008; Siegel *et al.*, 2012). Modified grains can be developed to silence immunostimulatory sequences, and a zonulin inhibitor, larazotide (AT-1001), has shown promise in clinical trials (Setty *et al.*, 2008; Schuppan *et al.*, 2009; Lionetti & Catassi, 2011). Rho/Rho kinase inhibition may reverse the gluten-dependent increase in intestinal permeability in these patients (Utech *et al.*, 2005). Immunotherapy is also being investigated, and IL-15 blocking antibodies have shown promise in inducing intra-epithelial lymphocytes apoptosis in the intestinal epithelium of human IL-15 transgenic mouse models (Green & Cellier, 2007; Rashtak & Murray, 2012). A lot of work and study should be done in these areas because focusing simply on a gluten-free diet won't benefit people with CD because obtaining a gluten-free diet involves several criteria, including availability, economy, and contamination. Yet even if you follow a gluten-free diet, a gluten-free diet alone may not be sufficient to treat all forms of celiac disease, such as refractory CD.

CONCLUSION

CD is a multifaceted disorder that is associated with a range of other diseases, making it challenging for individuals to recognize their condition. In this condition, the lining of the intestine, which houses approximately 70% of the body's immune cells, undergoes damage. As a result, the absorption of nutrients is impaired, leading to diverse immune responses. When nutrition absorption is compromised, the body does not receive the necessary nutrients required for optimal performance. This deficiency in nutrients such as B12, iron, magnesium, and others hinder the body's ability to function normally. Consequently, a variety of hormones and body parts are adversely affected, resulting in many health conditions such as mental disorders, thyroid disorders, osteoporosis, infertility, and more. The intestine lining triggers immune responses that contribute to the development of autoimmune disorders linked to CD. These immune responses extend beyond gluten-specific reactions and produce different antibodies. These antibodies not only cause intestinal damage but also activate interleukins, tumor necrosis factors, and cytokinins, leading to effects that surpass the intestine lining. Consequently, CD is not solely an autoimmune disorder; it extends to other areas and is associated with various tumor and cancers. Individuals with CD have an increased risk of developing certain types of cancer, particularly lymphomas and gastrointestinal cancers. The underlying mechanisms for this association are not fully understood, but it is believed to be related to the chronic inflammation and immune dysregulation present in CD. Regular monitoring and early detection of cancer are important for individuals with CD to manage their health effectively. Therefore, CD is not limited to being an autoimmune disorder but has far-reaching implications.

That's why there is a pressing need to raise awareness about CD and its potential complications. It is crucial to emphasize the importance of educating people about CD and its various

manifestations. Furthermore, there is a critical need to promote awareness about the diagnostic tests available for CD. It is imperative that individuals suspected of having CD undergo proper diagnostic testing before initiating a gluten-free diet or any other precautionary measures. Starting a gluten-free diet without a confirmed diagnosis may lead to false-negative results and hinder accurate identification of the condition. Therefore, it is essential to prioritize diagnostic tests as the initial step in managing CD. Once an individual has been positively diagnosed with CD, it is of utmost importance to take the prescribed treatment and precautions seriously. Adhering to a strict gluten-free diet (GFD) becomes essential to avoid the adverse consequences associated with CD. Gut microbiota has been found to play a significant role in the recovery and management of celiac disease (CD). Probiotics and prebiotics are beneficial substances that can positively influence the composition and activity of the gut microbiota. Immunotherapy, enzyme therapy and vaccines are among the areas of active investigation. These emerging approaches offer hope for more effective management and treatment options for individuals living with celiac disease. Neglecting or leaving CD untreated can result in severe complications and worsen the overall health condition.

REFERENCES

- Bluestone, J. A., Bour-Jordan, H., Cheng, M., & Anderson, M. (2015). T cells in the control of organ-specific autoimmunity. *The Journal of Clinical Investigation*, 125(6), 2250-2260. <https://doi.org/10.1172/JCI78089>
- Cacciari, E., Salardi, S., Lazzari, R., Cicognani, A., Collina, A., Pirazzoli, P., Tassoni, P., Biasco, G., Corazza, G. R., & Cassio, A. (1983). Short stature and celiac disease: A relationship to consider even in patients with no gastrointestinal tract symptoms. *The Journal of Pediatrics*, 103(5), 708-711. [https://doi.org/10.1016/s0022-3476\(83\)80462-4](https://doi.org/10.1016/s0022-3476(83)80462-4)
- Catassi, C., & Fasano, A. (2010). Celiac disease diagnosis: Simple rules are better than complicated algorithms. *The American Journal of Medicine*, 123(8), 691-693. <https://doi.org/10.1016/j.amjmed.2010.02.019>
- Cellier, C., Delabesse, E., Helmer, C., Patey, N., Matuchansky, C., Jabri, B., Macintyre, E., Cerf-Bensussan, N., & Brousse, N. (2000). Refractory sprue, coeliac disease, and enteropathy-associated T-cell lymphoma. French Coeliac Disease Study Group. *The Lancet*, 356(9225), 203-208. [https://doi.org/10.1016/s0140-6736\(00\)02481-8](https://doi.org/10.1016/s0140-6736(00)02481-8)
- Cosnes, J., Cellier, C., Viola, S., Colombel, J.-F., Michaud, L., Sarles, J., Hugot, J.-P., Ginies, J.-L., Dabadie, A., Mouterde, O., Allez, M., & Nion-Larmurier, I. (2008). Incidence of autoimmune diseases in celiac disease: Protective effect of the gluten-free diet. *Clinical Gastroenterology and Hepatology*, 6(7), 753-758. <https://doi.org/10.1016/j.cgh.2007.12.022>
- De Angelis, M., Rizzello, C. G., Fasano, A., Clemente, M. G., De Simone, C., Silano, M., De Vincenzi, M., Losito, I., & Gobetti, M. (2006). VSL#3 probiotic preparation has the capacity to hydrolyze gliadin polypeptides responsible for Celiac Sprue. *Biochimica et Biophysica Acta (BBA) - Molecular Basis of Disease*, 1762(1), 80-93. <https://doi.org/10.1016/j.bbdis.2005.09.008>
- de Sousa Moraes, L. F., Grzeskowiak, L. M., de Sales Teixeira, T. F., & do Carmo Gouveia Peluzio, M. (2014). Intestinal Microbiota and Probiotics in Celiac Disease. *Clinical Microbiology Reviews*, 27(3), 482-489. <https://doi.org/10.1128/CMR.00106-13>
- Dewar, D. H., & Ciclitira, P. J. (2005). Clinical features and diagnosis of celiac disease. *Gastroenterology*, 128(4), S19-S24. <https://doi.org/10.1053/j.gastro.2005.02.010>
- Di Sabatino, A., & Corazza, G. R. (2009). Coeliac disease. *The Lancet*, 373(9673), 1480-1493. [https://doi.org/10.1016/S0140-6736\(09\)60254-3](https://doi.org/10.1016/S0140-6736(09)60254-3)
- Dieterich, W., Ehnis, T., Bauer, M., Donner, P., Volta, U., Riecken, E. O., & Schuppan, D. (1997). Identification of tissue transglutaminase as the autoantigen of celiac disease. *Nature Medicine*, 3, 797-801.

- <https://doi.org/10.1038/nm0797-797>
- Elfström, P., Granath, F., Ye, W., & Ludvigsson, J. F. (2012). Low risk of gastrointestinal cancer among patients with celiac disease, inflammation, or latent celiac disease. *Clinical Gastroenterology and Hepatology*, 10(1), 30-36. <https://doi.org/10.1016/j.cgh.2011.06.029>
- Farthing, M. J., Rees, L. H., Edwards, C. R., & Dawson, A. M. (1983). Male gonadal function in coeliac disease: 2. Sex hormones. *Gut*, 24(2), 127-135. <https://doi.org/10.1136/gut.24.2.127>
- Fasano, A. (1999). Tissue transglutaminase: The Holy Grail for the diagnosis of celiac disease, at last? *The Journal of Pediatrics*, 134(2), 134-135. [https://doi.org/10.1016/s0022-3476\(99\)70402-6](https://doi.org/10.1016/s0022-3476(99)70402-6)
- Fasano, A., & Catassi, C. (2001). Current approaches to diagnosis and treatment of celiac disease: An evolving spectrum. *Gastroenterology*, 120(3), 636-651. <https://doi.org/10.1053/gast.2001.22123>
- Fasano, A., Araya, M., Bhatnagar, S., Cameron, D., Catassi, C., Dirks, M., Mearin, M. L., Ortigosa, L., Phillips, A., & Celiac Disease Working Group, FISPUGHAN. (2008). Federation of International Societies of Pediatric Gastroenterology, Hepatology, and Nutrition consensus report on celiac disease. *Journal of Pediatric Gastroenterology and Nutrition*, 47(2), 214-219. <https://doi.org/10.1097/MPG.0b013e318181afed>
- Fehniger, T. A., & Caligiuri, M. A. (2001). Interleukin 15: Biology and relevance to human disease. *Blood*, 97(1), 14-32. <https://doi.org/10.1182/blood.v97.1.14>
- Fernández, A., González, L., & de la Fuente, J. (2010). Coeliac disease, Clinical features in adult populations. *Revista Española de Enfermedades Digestivas*, 102(8), 466-471. <https://doi.org/10.4321/S1130-01082010000800002>
- Fouda, M. A., Khan, A. A., Sultan, M., Rios, L. P., McAssey, K., & Armstrong, D. (2012). Evaluation and management of skeletal health in celiac disease: Position statement. *Canadian Journal of Gastroenterology*, 26, 819-829. <https://doi.org/10.1155/2012/823648>
- Freeman, H. J., Chopra, A., Clandinin, M. T., & Thomson, A. B. (2011). Recent advances in celiac disease. *World Journal of Gastroenterology*, 17(18), 2259-2272. <https://doi.org/10.3748/wjg.v17.i18.2259>
- Fry, L. (1995). Dermatitis herpetiformis. *Bailliere's Clinical Gastroenterology*, 9(2), 371-393. [https://doi.org/10.1016/0950-3528\(95\)90036-5](https://doi.org/10.1016/0950-3528(95)90036-5)
- George, E. K., Hertzberger-ten Cate, R., van Suijlekom-Smit, L. W., von Blomberg, B. M., Stapel, S. O., van Elburg, R. M., & Mearin, M. L. (1996). Juvenile chronic arthritis and coeliac disease in The Netherlands. *Clinical and Experimental Rheumatology*, 14(5), 571-575.
- Gobbi, G. (2005). Coeliac disease, epilepsy & cerebral calcifications. *Brain and Development*, 27(3), 189-200. <https://doi.org/10.1016/j.braindev.2004.05.003>
- Green, P. H. R., & Cellier, C. (2007). Celiac disease. *The New England Journal of Medicine*, 357(17), 1731-1743. <https://doi.org/10.1056/NEJMr071600>
- Groll, A., Preece, M. A., Candy, D. C. A., Tanner, J. M., & Harries, J. T. (1980). Short stature as the primary manifestation of coeliac disease. *The Lancet*, 316(8204), 1097-1099. [https://doi.org/10.1016/s0140-6736\(80\)92538-6](https://doi.org/10.1016/s0140-6736(80)92538-6)
- Guidetti, C. S., Solerio, E., Scaglione, N., Aimo, G., & Mengozzi, G. (2001). Duration of gluten exposure in adult coeliac disease does not correlate with the risk for autoimmune disorders. *Gut*, 49(4), 502-505. <https://doi.org/10.1136/gut.49.4.502>
- Hadithi, M., von Blomberg, B. M. E., Crusius, J. B. A., Bloemena, E., Kostense, P. J., Meijer, J. W. R., Mulder, C. J. J., Stehouwer, C. D. A., & Peña, A. S. (2007). Accuracy of serologic tests and HLA-DQ typing for diagnosing celiac disease. *Annals of Internal Medicine*, 147(5), 294-302. <https://doi.org/10.7326/0003-4819-147-5-200709040-00003>
- Hopman, E. G. D., le Cessie, S., von Blomberg, B. M. E., & Mearin, M. L. (2006). Nutritional management of the gluten-free diet in young people with celiac disease in The Netherlands. *Journal of Pediatric Gastroenterology and Nutrition*, 43(1), 102-108. <https://doi.org/10.1097/01.mpg.0000228102.89454.eb>
- Hummel, M., Bonifacio, E., Stern, M., Dittler, J., Schimmel, A., & Ziegler, A. G. (2000). Development of celiac disease-associated antibodies in offspring of parents with type I diabetes. *Diabetologia*, 43, 1005-1011. <https://doi.org/10.1007/s001250051483>
- Jabri, B., Kasarda, D. D., & Green, P. H. R. (2005). Innate and adaptive immunity: The yin and yang of celiac disease. *Immunological Reviews*, 206(1), 219-231. <https://doi.org/10.1111/j.0105-2896.2005.00294.x>
- Jaskowski, T. D., Hamblin, T., Wilson, A. R., Hill, H. R., Book, L. S., Meyer, L. J., Zone, J. J., & Hull, C. M. (2009). IgA anti-epidermal transglutaminase antibodies in dermatitis herpetiformis and pediatric celiac disease. *The Journal of Investigative Dermatology*, 129(11), 2728-2730. <https://doi.org/10.1038/jid.2009.142>
- Kasarda, D. D., Okita, T. W., Bernardin, J. E., Baecker, P. A., Nimmo, C. C., Lew, E. J., Dietler, M. D., & Greene, F. C. (1984). Nucleic acid (cDNA) and amino acid sequences of alpha-type gliadins from wheat (*Triticum aestivum*). *Proceedings of the National Academy of Sciences of the United States of America*, 81(15), 4712-4716. <https://doi.org/10.1073/pnas.81.15.4712>
- Kau, A. L., Ahern, P. P., Griffin, N. W., Goodman, A. L., & Gordon, J. I. (2011). Human nutrition, the gut microbiome, and immune system: Envisioning the future. *Nature*, 474, 327-336. <https://doi.org/10.1038/nature10213>
- Kochhar, G. S., Singh, T., Gill, A., & Kirby, D. F. (2016). Celiac disease: Managing a multisystem disorder. *Cleveland Clinic Journal of Medicine*, 83(3), 217-227. <https://doi.org/10.3949/ccjm.83a.14158>
- Kumar, V., Rajadhyaksha, M., & Wortsman, J. (2001). Celiac Disease-Associated Autoimmune Endocrinopathies. *Clinical and Diagnostic Laboratory Immunology*, 8(4), 678. <https://doi.org/10.1128/CDLI.8.4.678-685.2001>
- Lähdeaho, M.-L., Kaukinen, K., Laurila, K., Vuotikka, P., Koivurova, O.-P., Kärjä-Lahdensuu, T., Marcantonio, A., Adelman, D. C., & Mäki, M. (2014). Glutenase ALV003 attenuates gluten-induced mucosal injury in patients with celiac disease. *Gastroenterology*, 146(7), 1649-1658. <https://doi.org/10.1053/j.gastro.2014.02.031>
- Lebwohl, B., Eriksson, H., Hansson, J., Green, P. H. R., & Ludvigsson, J. F. (2014). Risk of cutaneous malignant melanoma in patients with celiac disease: A population-based study. *Journal of the American Academy of Dermatology*, 71(2), 245-248. <https://doi.org/10.1016/j.jaad.2014.03.029>
- Lindfors, K., Blomqvist, T., Juuti-Uusitalo, K., Stenman, S., Venäläinen, J., Mäki, M., & Kaukinen, K. (2008). Live probiotic Bifidobacterium lactis bacteria inhibit the toxic effects induced by wheat gliadin in epithelial cell culture. *Clinical and Experimental Immunology*, 152(3), 552-558. <https://doi.org/10.1111/j.1365-2249.2008.03635.x>
- Lionetti, E., & Catassi, C. (2011). New clues in celiac disease epidemiology, pathogenesis, clinical manifestations, and treatment. *International Reviews of Immunology*, 30(4), 219-231. <https://doi.org/10.3109/08830185.2011.602443>
- Logan, R. F. A., Rifkind, E. A., Turner, I. D., & Ferguson, A. (1989). Mortality in celiac disease. *Gastroenterology*, 97, 265-271. [https://doi.org/10.1016/0016-5085\(89\)90060-7](https://doi.org/10.1016/0016-5085(89)90060-7)
- Logan, R. F., Tucker, G., Rifkind, E. A., Heading, R. C., & Ferguson, A. (1983). Changes in clinical features of coeliac disease in adults in Edinburgh and the Lothians 1960-79. *British Medical Journal*, 286(6359), 95-97.
- Mahadev, S., Laszkowska, M., Sundström, J., Björkholm, M., Lebwohl, B., Green, P. H. R., & Ludvigsson, J. F. (2018). Prevalence of Celiac Disease in Patients With Iron Deficiency Anemia-A Systematic Review With Meta-analysis. *Gastroenterology*, 155(2), 374-382.e1. <https://doi.org/10.1053/j.gastro.2018.04.016>
- Mahmud, F. H., Murray, J. A., Kudva, Y. C., Zinsmeister, A. R., Dierkhising, R. A., Lahr, B. D., Dyck, P. J., Kyle, R. A., El-Youssef, M., Burgart, L. J., Van Dyke, C. T., Brogan, D. L., & Melton, L. J. (2005). Celiac Disease in Type 1 Diabetes Mellitus in a North American Community, Prevalence, Serologic Screening, and Clinical Features. *Mayo Clinic Proceedings*, 80(11), 1429-1434. <https://doi.org/10.4065/80.11.1429>
- Maiuri, L., Ciacchi, C., Auricchio, S., Brown, V., Quarantino, S., & Londei, M. (2000). Interleukin 15 mediates epithelial changes in celiac disease. *Gastroenterology*, 119(4), 996-1006. <https://doi.org/10.1053/gast.2000.18149>
- Meyer, D., Stavropoulos, S., Diamond, B., Shane, E., & Green, P. H. (2001). Osteoporosis in a north american adult population with celiac disease. *The American Journal of Gastroenterology*, 96(1), 112-119. <https://doi.org/10.1111/j.1572-0241.2001.03507.x>
- Mora, S., Barera, G., Beccio, S., Proverbio, M. C., Weber, G., Bianchi, C., & Chiumello, G. (1999). Bone density and bone metabolism are normal after long-term gluten-free diet in young celiac patients. *The American Journal of Gastroenterology*, 94(2), 398-403. https://doi.org/10.1111/j.1572-0241.1999.867_r.x
- Murray, J. A., Watson, T., Clearman, B., & Mitros, F. (2004). Effect of a gluten-free diet on gastrointestinal symptoms in celiac disease. *The American Journal of Clinical Nutrition*, 79(4), 669-673. <https://doi.org/10.1093/ajcn/79.4.669>
- Narula, N., Wong, E. C. L., Dehghan, M., Mente, A., Rangarajan, S.,

- Lanas, F., Lopez-Jaramillo, P., Rohatgi, P., Lakshmi, P.V.M., Varma, R. P., Orlandini, A., Avezum, A., Wielgosz, A., Poirier, P., Almadi, M. A., Altuntas, Y., Ng, K. K., Chifamba, J., Yeates, K.,... Yusuf, S. (2021). Association of ultra-processed food intake with risk of inflammatory bowel disease: Prospective cohort study. *BMJ*, 374, n1554. <https://doi.org/10.1136/bmj.n1554>
- Nepom, G. T., & Kwok, W. W. (1998). Molecular basis for HLA-DQ associations with IDDM. *Diabetes*, 47(8), 1177-1184. <https://doi.org/10.2337/diab.47.8.1177>
- Ouaka-Kchaou, A., Ennaifer, R., Elloumi, H., Gargouri, D., Hefaidh, R., Kochlef, A., Romani, M., Kilani, A., Kharrat, J., & Ghorbel, A. (2008). Autoimmune Diseases in Coeliac Disease, Effect of Gluten Exposure. *Therapeutic Advances in Gastroenterology*, 1(3), 169-172. <https://doi.org/10.1177/1756283X08096612>
- Parzanese, I., Qehajaj, D., Patrinicola, F., Aralica, M., Chiriva-Internati, M., Stifter, S., Elli, L., & Grizzi, F. (2017). Celiac disease: From pathophysiology to treatment. *World Journal of Gastrointestinal Pathophysiology*, 8(2), 27-38. <https://doi.org/10.4291/wjgp.v8.i2.27>
- Pellecchia, M. T., Scala, R., Filla, A., De Michele, G., Ciacci, C., & Barone, P. (1999). Idiopathic cerebellar ataxia associated with celiac disease: Lack of distinctive neurological features. *Journal of Neurology, Neurosurgery, and Psychiatry*, 66(1), 32-35. <https://doi.org/10.1136/jnnp.66.1.32>
- Pender, S. L., Tickle, S. P., Docherty, A. J., Howie, D., Wathen, N. C., & MacDonald, T. T. (1997). A major role for matrix metalloproteinases in T cell injury in the gut. *Journal of Immunology*, 158(4), 1582-1590. <https://doi.org/10.4049/jimmunol.158.4.1582>
- Pozo-Rubio, T., Olivares, M., Nova, E., De Palma, G., Mujico, J. R., Ferrer, M. D., Marcos, A., & Sanz, Y. (2012). Immune development and intestinal microbiota in celiac disease. *Clinical and Developmental Immunology*, 2012, 654143. <https://doi.org/10.1155/2012/654143>
- Rashtak, S., & Murray, J. A. (2012). Review article: Coeliac disease, new approaches to therapy. *Alimentary Pharmacology and Therapeutics*, 35(7), 768-781. <https://doi.org/10.1111/j.1365-2036.2012.05013.x>
- Roehr, C. C., Edenharter, G., Reimann, S., Ehlers, I., Worm, M., Zuberbier, T., & Niggemann, B. (2004). Food allergy and non-allergic food hypersensitivity in children and adolescents. *Clinical and Experimental Allergy*, 34(10), 1534-1541. <https://doi.org/10.1111/j.1365-2222.2004.02080>
- Roshan, B., Leffler, D. A., Jamma, S., Dennis, M., Sheth, S., Falchuk, K., Najarian, R., Goldsmith, J., Tariq, S., Schuppan, D., & Kelly, C. P. (2011). The incidence and clinical spectrum of refractory celiac disease in a north american referral center. *The American Journal of Gastroenterology*, 106(5), 923-928. <https://doi.org/10.1038/ajg.2011.104>
- Rubio-Tapia, A., & Murray, J. A. (2007). The liver in celiac disease. *Hepatology*, 46(5), 1650-1658. <https://doi.org/10.1002/hep.21949>
- Rubio-Tapia, A., Hill, I. D., Kelly, C. P., Calderwood, A. H., & Murray, J. A. (2013). ACG clinical guidelines: Diagnosis and management of celiac disease. *The American Journal of Gastroenterology*, 108(5), 656-676. <https://doi.org/10.1038/ajg.2013.79>
- Sategna-Guidetti, C., Grosso, S. B., Grosso, S., Mengozzi, G., Aimo, G., Zaccaria, T., Di Stefano, M., & Isaia, G. C. (2000). The effects of 1-year gluten withdrawal on bone mass, bone metabolism and nutritional status in newly-diagnosed adult coeliac disease patients. *Alimentary Pharmacology and Therapeutics*, 14, 35-43. <https://doi.org/10.1046/j.1365-2036.2000.00671.x>
- Sblattero, D., Berti, I., Trevisiol, C., Marzari, R., Tommasini, A., Bradbury, A., Fasano, A., Ventura, A., & Not, T. (2000). Human recombinant tissue transglutaminase ELISA: an innovative diagnostic assay for celiac disease. *The American Journal of Gastroenterology*, 95(5), 1253-1257. [https://doi.org/10.1016/S0002-9270\(00\)00810-8](https://doi.org/10.1016/S0002-9270(00)00810-8)
- Schuppan, D. (2000). Current concepts of celiac disease pathogenesis. *Gastroenterology*, 119(1), 234-242. <https://doi.org/10.1053/gast.2000.8521>
- Schuppan, D., Junker, Y., & Barisani, D. (2009). Celiac disease: From pathogenesis to novel therapies. *Gastroenterology*, 137(6), 1912-1933. <https://doi.org/10.1053/j.gastro.2009.09.008>
- Setty, M., Hormaza, L., & Guandalini, S. (2008). Celiac disease: Risk assessment, diagnosis, and monitoring. *Molecular Diagnosis and Therapy*, 12, 289-298. <https://doi.org/10.1007/BF03256294>
- Shan, L., Molberg, Ø., Parrot, I., Hausch, F., Filiz, F., Gray, G. M., Sollid, L. M., & Khosla, C. (2002). Structural basis for gluten intolerance in celiac sprue. *Science (New York, N.Y.)*, 297(5590), 2275-2279. <https://doi.org/10.1126/science.1074129>
- Siegel, M., Garber, M. E., Spencer, A. G., Botwick, W., Kumar, P., Williams, R. N., Kozuka, K., Shreenivas, R., Pratha, V., & Adelman, D. C. (2012). Safety, tolerability, and activity of ALV003: Results from two phase 1 single, escalating-dose clinical trials. *Digestive Diseases and Sciences*, 57, 440-450. <https://doi.org/10.1007/s10620-011-1906-5>
- Sommer, A., Tarvotjo, I., & Katz, J. (1987). Increased risk of xerophthalmia following diarrhea and respiratory disease. *The American Journal of Clinical Nutrition*, 45(5), 977-980. <https://doi.org/10.1093/ajcn/45.5.977>
- Stazi, A. V., & Trinti, B. (2010). Selenium status and over-expression of interleukin-15 in celiac disease and autoimmune thyroid diseases. *Annali Dell'Istituto Superiore Di Sanita*, 46, https://doi.org/10.4415/ANN_10_04_06
- Summaries for patients. (2013). Risk for lymphoma and the results of follow-up gut biopsies in patients with celiac disease. *Annals of Internal Medicine*, 159(3), 1-20. <https://doi.org/10.7326/0003-4819-159-3-201308060-00002>
- Swinson, C. M., Coles, E. C., Slavin, G., & Booth, C. C. (1983). Coeliac disease and malignancy. *The Lancet*, 321(8316), 111-115. [https://doi.org/10.1016/s0140-6736\(83\)91754-3](https://doi.org/10.1016/s0140-6736(83)91754-3)
- Turnbaugh, P. J., Ridaura, V. K., Faith, J. J., Rey, F. E., Knight, R., & Gordon, J. I. (2009). The Effect of Diet on the Human Gut Microbiome: A Metagenomic Analysis in Humanized Gnotobiotic Mice. *Science Translational Medicine*, 1(6), 6ra14. <https://doi.org/10.1126/scitranslmed.3000322>
- Utech, M., Ivanov, A. I., Samarin, S. N., Bruewer, M., Turner, J. R., Mrsny, R. J., Parkos, C. A., & Nusrat, A. (2005). Mechanism of IFN-gamma-induced endocytosis of tight junction proteins: Myosin II-dependent vacuolization of the apical plasma membrane. *Molecular Biology of the Cell*, 16(10), 5040-5052. <https://doi.org/10.1091/mbc.e05-03-0193>
- van der Pals, M., Ivarsson, A., Norström, F., Högborg, L., Svensson, J., & Carlsson, A. (2014). Prevalence of Thyroid Autoimmunity in Children with Celiac Disease Compared to Healthy 12-Year Olds. *Autoimmune Diseases*, 2014, 417356. <https://doi.org/10.1155/2014/417356>
- van Heel, D. A., Franke, L., Hunt, K. A., Gwilliam, R., Zhernakova, A., Inouye, M., Wapenaar, M. C., Barnardo, M. C. N. M., Bethel, G., Holmes, G. K. T., Feighery, C., Jewell, D., Kelleher, D., Kumar, P., Travis, S., Walters, J. R. F., Sanders, D. S., Howdle, P., Swift, J.,... Wijmenga, C. (2007). A genome-wide association study for celiac disease identifies risk variants in the region harboring IL2 & IL21. *Nature Genetics*, 39, 827-829. <https://doi.org/10.1038/ng2058>
- Villanacci, V., Ceppa, P., Tavani, E., Vindigni, C., & Volta, U. (2011). Coeliac disease: The histology report. *Digestive and Liver Disease*, 43, S385-S395. [https://doi.org/10.1016/S1590-8658\(11\)60594-X](https://doi.org/10.1016/S1590-8658(11)60594-X)
- Wieser, H. (2007). Chemistry of gluten proteins. *Food Microbiology*, 24(2), 115-119. <https://doi.org/10.1016/j.fm.2006.07.004>
- Wolters, V. M., & Wijmenga, C. (2008). Genetic background of celiac disease and its clinical implications. *The American Journal of Gastroenterology*, 103(1), 190-195. <https://doi.org/10.1111/j.1572-0241.2007.01471.x>
- Wu, H.-J., Ivanov, I. I., Darce, J., Hattori, K., Shima, T., Umesaki, Y., Littman, D. R., Benoist, C., & Mathis, D. (2010). Gut-residing segmented filamentous bacteria drive autoimmune arthritis via T helper 17 cells. *Immunity*, 32(6), 815-827. <https://doi.org/10.1016/j.immuni.2010.06.001>
- Zone, J. J., Meyer, L. J., & Petersen, M. J. (1996). Deposition of granular IgA relative to clinical lesions in dermatitis herpetiformis. *Archives of Dermatology*, 132(8), 912-918. <https://doi.org/10.1001/archderm.1996.03890320060010>