

Hepatoprotective Activity of *Aegle marmelos* in CCl₄ Induced Toxicity - An *In-vivo* Study

P. Sumitha and T. Thirunalasundari*

Department of Biotechnology, Bharathidasan University, Tiruchirappalli - 620 024, Tamil Nadu, India

Article Info

Article History

Received : 19-05-2011
Revised : 03-08-2011
Accepted : 07-08-2011

*Corresponding Author

Tel : +91-9443145690
(M)
+91-431 2407086
(O)

Fax : +91-431 24070 45

Email:

drttns@bdu.ac.in / drttns@gmail.com
sumitha158@hotmail.com

Summary

Medicinal plants are of great importance for healthy living of an individual. *Aegle marmelos* is one of the Indian medicinal plant, which has enormous medicinal values against various diseases / disorders and it has traditionally been used by ayurvedic people for the treatment of liver problems. This study is aimed to investigate the hepatoprotective effect of crude ethanolic extract of the leaves of *A. marmelos* (AMEE) in carbon tetrachloride (CCl₄) induced toxicity in mice. The ethanolic extract at a dose of 500mg/kg body weight when given orally exhibited a significant (P<0.05) protective effect evidenced by lowering the levels of enzymes like serum glutamate pyruvate transaminase, serum glutamate oxaloacetate transaminase, alkaline phosphatase, bilirubin, total cholesterol, triglycerides, low density lipoprotein and very low density lipoprotein but there was an increase in the level of high density lipoprotein as compared to CCl₄ induced group. It was also proved by increased level of antioxidant enzymes in *A. marmelos* treated group. Lipid peroxidation was significantly lowered in CCl₄ treated group followed by plant extract treated group. These biochemical observations were supported by histopathological examination of liver sections. From these results, it was concluded that the ethanolic extract of *Aegle marmelos* possesses hepatoprotective activity which needs to be proved further to get a lead molecule for hepatoprotection.

©ScholarJournals, SSR

Key Words: *Aegle marmelos*; Hepatoprotection; Carbon tetrachloride; Antioxidant

Introduction

Starting from ancient period medicinal plants play a vital role in the treatment of several diseases. In traditional systems of medicine many plants were used as cure for liver problems. Medicinal plants possess valuable bioactive compounds that protects human from various complications. *Aegle marmelos* is one such plant that was used quite often in traditional system of medicine. It belongs to the family Rutaceae, and popularly known as "Bael tree" [1] [2]. It is indigenous to India and found wild all over the Sub-Himalayan forests, in Central, and South India. The plant is reported to have multiple therapeutic properties such as anti-inflammatory, antipyretic and analgesic [3] [4], anti diabetic [5] [6] [7], antifungal [8], antimicrobial, antibacterial and anti parasitic [9], anti cancer [10] and hepatoprotective [11] activity.

Liver diseases are considered as fatal & life threatening. It creates a serious challenge to public health. Liver diseases are due to infection and / or exposure of liver to various toxic substances such as drugs or alcohol. Some times over dosage of drugs can also lead to liver damage. Now-a-day's due to inadequacy of liver protective agents, researchers and traditional medicine practioners concentrate in herbal based remedies for various liver disorders. Modern medicines have little to offer for alleviation of hepatic disorders. There was no safe hepatoprotective drug available for the treatment of liver disorders [12] [13]. Therefore, many folk remedies from plant source are used for the protection of hepatic damages starting from ancient period. Hence the present work was

undertaken to scientifically prove the hepatoprotective nature of *Aegle marmelos* by an *in-vivo* study.

Materials and Methods

Collection and identification of plant material

The plant material i.e leaves of *Aegle marmelos* were collected from Bharathidasan University campus, Tiruchirappalli in November 2010. The plant was identified by the Botanist of Bharathidasan University, Tiruchirappalli and a voucher specimen (herbarium) was deposited in the Department of Botany, St. Joseph College, Tiruchirappalli and the voucher number was obtained. The voucher number of it is SJCBO1262.

Processing & preparation of crude extract

The collected plant material was shade dried and it was powdered using mixer grinder (Smith). Care was taken to avoid fungal contamination while drying. The dried plant material was subjected to cold extraction by soaking 100g of dry powder in 200ml of distilled ethanol for three days at room temperature with occasional shaking. Then it was subjected for centrifugation. The supernatant was collected and it was filtered using whatman filter paper No. 1 (125mm) and the filtrate was evaporated to dryness in an evaporating dish at room temperature to obtain a semi solid substance. Then the dried extract was weighed and stored in an air tight container for hepatoprotective activity testing in mice model.

Experimental animals

Healthy Swiss albino male mice weighing between 25-30g were procured from Animal medicine unit, TANUVAS, Mathavaram, Chennai. The animals were kept in polypropylene cages and were fed with standard feed and water ad libitum. Animals were maintained in standard lab conditions with 12-hours cycle of light & dark. Room temperature was kept at $22 \pm 2^\circ\text{C}$ and humidity was maintained at $50 \pm 5\%$. The protocol was approved by animal ethics committee of the institution constituted (AECC) for the purpose as per CPCSEA guidelines.

Experimental design for hepatoprotective activity

A total of 20 animals were taken and were divided into 5 groups of 4 animals each ($n=4$ / group). Group I (control) received olive oil orally for 14 days. Group II (hepatotoxin control) received a single dose of 0.2ml/kg of CCl_4 diluted with 0.2ml of olive oil in 1:1 ratio for 14 days alternatively. Group III (Test) were administered with single dose of 0.2ml/kg of CCl_4 along with vehicle alternatively for 14 days and it was followed by the treatment with 500mg/kg of *Aegle marmelos* leaf extract orally for 21 days. Group IV (Hepatoprotective agent control) animals were administered with CCl_4 for 14 days & followed by the treatment with 100mg/kg of known hepatoprotective agent (silymarin) for 21 days. Group V (plant control) animals received 500mg/kg of *Aegle marmelos* leaf extract orally for 21 days. On 22nd day, the animals were anaesthetized using chloroform and blood was collected by cardiac puncture. Serum was separated by centrifugation of blood at 3,000 rpm for 10 min and the separated serum was used for further biochemical analysis.

Biochemical analysis

Liver pathophysiological enzymes such as aspartate transaminase, alanine transaminase, alkaline phosphatase and lipid profile - total cholesterol, VLDL, HDL, triglycerides and bilirubin were estimated by using commercially available kits (AGAPEE Diagnostic, Kerala and Ensure Biotech Pvt, Hyderabad, India) and as per the manufacturer's instruction.

Measurement of CCl_4 mediated oxidative stress

The activities of enzymatic antioxidants such as SOD [14], catalase [15] and GPx [16] were assayed in the hepatic tissue homogenate of control and experimental group of mice. Further, the level of lipid peroxide - Malondialdehyde (MDA) [17] was also determined in the serum and liver tissue homogenate of control and experimental groups of mice.

Histopathological Studies

A portion of the liver was cut into two to three pieces approximately of 6mm³ size and fixed in phosphate buffered 10% formaldehyde solution. After embedding in paraffin wax,

thin sections of 5 μm thickness were cut and stained with haematoxylin-eosin. The stained sections were made into permanent slides and examined [18] under high resolution microscope (Adelta optec, model: AP40) with photographic facility and photomicrographs were taken.

Statistical analysis

The datas were analysed by one way analysis of variance (ANOVA) and it was followed by Bonferoni test for comparison using SPSS software version 16.0 and the $P < 0.05$ was considered as statistically significant.

Results

Assessment of hepatoprotective activity

Ethanollic extract of *Aegle marmelos* (500mg/kg bw) when given orally for 21 days showed hepatoprotective activity in carbon tetrachloride induced hepatic damage in mice. Table 1 showed a significant increase in the level of liver enzymes like SGOT, SGPT, ALP and bilirubin in CCl_4 intoxicated animals when compared with that of the control group of mice. CCl_4 induced animals treated with plant extract, were slowly recovered from hepatic injury and was evidenced by lower level of liver enzymes. These results were observed in *A. marmelos* & silymarin treated group. There was no change in plant control group. Hepatic injury caused by CCl_4 administration at a dose of 0.2ml/kg body weight showed significant increase in the lipid profile, viz. total cholesterol, triglycerides, LDL & VLDL levels in liver tissue. Whereas HDL level was decreased as compared to that of control group of mice ($p < 0.05$). However, treatment with *A. marmelos* at a dose of 500mg/kg and a known hepatoprotective agent silymarin (100mg/kg) to CCl_4 induced group of mice showed significant reduction in liver cholesterol, triglyceride, VLDL and LDL. On the other hand HDL level was increased compared to CCl_4 treated group and also no change was observed in plant control (Table 2).

The effect of *A. marmelos* on the activities of enzymatic antioxidants such as catalase, GPx, & SOD in serum of control and CCl_4 treated group showed significant reduction ($p < 0.05$). However, treatment with *A. Marmelos* as well as silymarin, increased the altered activities of these antioxidants in the liver of CCl_4 induced group and the change was significant ($p < 0.05$). These findings recommended that the free radicals released in the liver were effectively scavenged in the mouse treated with *A. marmelos* and silymarin. There was no change in the enzymatic antioxidants in plant control treated group. Malondialdehyde (MDA) content in liver of CCl_4 treated group was significantly higher than that of the control group and there was no change in MDA of the plant control group. However, MDA levels were significantly lowered in CCl_4 treated group followed by *A. marmelos* and silymarin ($p < 0.05$) (Table 3).

Table 1. Effect of ethanolic extract of *Aegle marmelos* leaves on liver enzymes and Bilirubin

Groups	SGOT (U/L)	SGPT (U/L)	ALP (U/L)	Total Bilirubin (mg/dl)	Direct Bilirubin (mg/dl)
Control	75.4 \pm 0.26	33.5 \pm 0.26	113.93 \pm 0.52	0.14 \pm 0.02	1.72 \pm 0.02
CCl_4 alone	210.33 \pm 0.16 ^a	103.66 \pm 1.45 ^a	218.86 \pm 0.48 ^a	0.33 \pm 0.02 ^a	2.17 \pm 0.01 ^a
CCl_4 + AMEE	157.4 \pm 0.264 ^b	76 \pm 0.57 ^b	154.43 \pm 0.29 ^b	0.24 \pm 0.02 ^b	1.82 \pm 0.03 ^b
CCl_4 + Silymarin	154.96 \pm 1.50 ^b	81 \pm 0.57 ^b	143.93 \pm 0.52 ^b	0.21 \pm 0.008 ^b	1.76 \pm 0.08 ^b
AMEE alone	74.3 \pm 0.28	37.56 \pm 0.20	113.66 \pm 2.02	0.24 \pm 0.02	1.62 \pm 0.03

Results were expressed as Mean \pm S.E.M [no' = 4]; a $P < 0.05$ compared with control group of mice; b $P < 0.05$ compared with CCl_4 induced group of mice.

Table 2. Effect of ethanolic extract of *Aegle marmelos* leaves on liver lipid profiles

Groups	Cholesterol (mg/dl)	Triglyceride (mg/dl)	HDL (mg/dl)	LDL (mg/dl)	VLDL (mg/dl)
Control	85.46 ± 0.23	78.26 ± 0.17	25.46 ± 0.26	44.4 ± 0.18	15.53 ± 0.23
CCl ₄ alone	137.46 ± 0.176 ^a	125.33 ± 1.45 ^a	20.4 ± 0.26 ^a	92.56 ± 0.20 ^a	24.53 ± 0.17 ^a
CCl ₄ + AMEE	102.43 ± 0.17 ^b	85.43 ± 0.14 ^b	21.66 ± 0.14 ^b	63.46 ± 0.14 ^b	17.5 ± 0.23 ^b
CCl ₄ + Silymarin	96.36 ± 0.23 ^b	80.56 ± 0.17 ^b	21.6 ± 0.17 ^b	58.36 ± 0.27 ^b	16.4 ± 0.17 ^b
AMEE alone	86.43 ± 0.14	76.5 ± 0.15	23.43 ± 0.176	47.46 ± 0.21	15.43 ± 0.12

Results were expressed as Mean ± S.E.M [n= 4]

a P<0.05 compared with control group of mice

b P<0.05 compared with CCl₄ induced group of mice

Table 3. Effect of ethanolic extract of *Aegle marmelos* on tissue enzymatic antioxidant activities

Groups	Catalase	GPX	SOD	MDA
Control	13.55 ± 0.023	2.57 ± 0.03	43.36 ± 0.02	2.62 ± 0.68
CCl ₄ alone	8.63 ± 0.03 ^a	1.34 ± 0.02 ^a	24.7 ± 0.04 ^a	7.56 ± 0.72
CCl ₄ + AMEE	12.44 ± 0.032 ^b	1.85 ± 0.026 ^b	42.15 ± 0.011 ^b	4.53 ± 0.56
CCl ₄ + Silymarin	12.39 ± 0.043 ^b	1.44 ± 0.017 ^b	48.28 ± 0.02 ^b	3.35 ± 0.51
AMEE alone	12.88 ± 0.023	2.84 ± 0.014	42.27 ± 0.02	2.64 ± 0.84

Catalase (U/mg of protein), Glutathione peroxidase (U/mg of protein) Superoxide dismutase (U/mg of protein).

MDA- nm/mg of protein

Results were expressed as Mean ± S.E.M [n= 4]

a P<0.05 compared with control group of mice

b P<0.05 compared with CCl₄ induced group of mice.

Light microscopic examination

Fig. 1 shows the light microscopy of Hematoxylin - Eosin stained hepatic tissue section of control and experimental groups of mice. Fig. 1. A shows the hepatic tissue of control mice exhibiting a concentric arrangement of the hepatocytes with sinusoidal cords around the central vein and portal tracts. Likewise, the sections of hepatic tissues of control group of mice treated with *A. marmelos* alone also revealed an equivalent architecture (Fig. 1. E). Fig. 1. B shows the section of liver tissue of CCl₄ treated group of mice exhibiting distortion in the arrangement of hepatocytes around the central vein, deformation of central vein, enlargement of hepatocytes, fatty infiltration of hepatocytes, congestion of sinusoids around central vein regions, and inflammation. Fig. 1.C demonstrates the cross section of liver tissues of CCl₄ induced group of mice treated with *A. marmelos* showing the normal hepatocytes arrangement around the central vein with abridged necrosis, declined fat accumulation, mild sinusoidal dilatation and reduction in nuclear enlargement. Similar results were observed in the liver tissues of CCl₄ induced group of mice treated with silymarin. Fig. 1. D shows similar pattern of hepatocytes arrangement & reduction in nuclear enlargement and are comparable with CCl₄ induced group of mice.

Discussion

Hepatotoxicity induced by CCl₄ is connected with severe impairment of the cell protection mechanism. CCl₄ is reductively bioactivated by cytochrome P₄₅₀ 2E1 into a trichloromethyl radical, which is subsequently converted into a peroxy radical in the presence of oxygen. These reactive free radical metabolites can covalently bind to macromolecules and also initiate lipid peroxidation [19] [20] [21]. In a study elevated serum marker enzymes such as SGOT, SGPT, ALP, LDH, ACP, gGT and 5' Nucleotidase were observed, due to CCl₄ treatment and the same were restored towards normalization in the plant treated group. The

biochemical parameters like total protein, total bilirubin, total cholesterol, triglycerides, and urea were also restored towards normal levels by the treatment of *Eclipta alba* and seeds of *Piper longum* [22]. Similarly, the present study also showed increased level of liver enzymes SGOT, SGPT, ALP and bilirubin in CCl₄ treated animals. However these enzymes level were lowered in CCl₄ intoxicated animals followed by treatment with plant extract. This revealed the hepatoprotective role of plant extract and the recovery of liver damage was at a significant level. The activity of serum lipid profile such as total cholesterol, triglycerides, LDL & VLDL were elevated, and this indicated deterioration in hepatic function due to the damage caused by CCl₄ administration. Whereas treatment of *A. marmelos* extract significantly declined the effect of CCl₄ induced damage and it was evidenced by the decreased level of total cholesterol, triglycerides, LDL & VLDL and increased level of HDL in *A. marmelos* treated group.

In several studies it has been shown that antioxidant action of plant extract plays an important role in protection against CCl₄ induced liver injury. Antioxidant enzymes like SOD, GSH-Px and catalase activities were significantly decreased in the liver in response to CCl₄ administration compared with normal control. CCl₄ induced oxidative damage of liver, where the level of antioxidant enzymes were significantly elevated by administration of *D. salina* to CCl₄ intoxicated mice [23]. Similarly the present study also showed reduced level of the enzymatic antioxidants such as catalase, glutathione peroxidase & superoxide dismutase in CCl₄ treated group when compared with the normal control group. However, elevated level of these antioxidant enzymes were observed in CCl₄ intoxicated group treated with *A. marmelos*. This proves that *A. marmelos* has the ability to restore these enzyme activities in CCl₄ damaged liver.

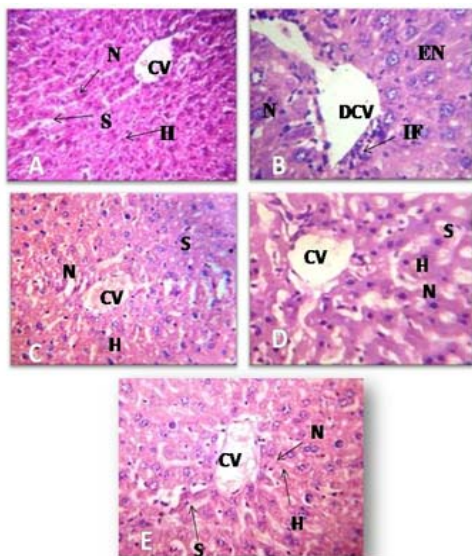


Fig. 1. Histopathology of liver tissues (400X). (A) Control showing normal cellular architecture with distinct hepatocyte; (B) CCl₄ alone shows deformation in central vein, Enlarged nucleus & Infiltration of cells; (C) CCl₄+AMEE treated group shows prominent nucleus, reduced infiltration & mild sinusoidal dilation; (D) CCl₄ +Silymarin: Cross section of liver treated with known hepatoprotective drug Silymarin in CCl₄ intoxicated mice shows similar pattern of hepatocytes arrangement; (E) AM alone treated group showing normal cellular architecture & there is no abnormalities. Nucleus (N), central vein (CV), hepatocytes (H), damaged central vein (DVC), enlarged nucleus & infiltration of cell (IF).

Histopathological studies also support the biochemical analysis. In a study paracetamol induced (500 mg/kg) hepatic damage in mice was treated with crude methanolic extract of *Andrographis paniculata* (10 mg/kg and 100 mg/kg) after 24 hours and 72 hours. Mice treated with 10 mg/kg of *A. paniculata* extract showed the presence of hepatocytes, which almost recovered to normal polyhedral shape with the development of clear cell lining and reduced vacuolated nuclei. Whereas mice treated with 100 mg/kg of *A. paniculata* extract showed complete recovery of hepatocytes with reduced vacuolations, normal hepatocytes, clear cell lining as well as absence of multinucleated giant cell [24]. This study also showed similar picture proving the hepatoprotective nature of *A. marmelos*.

Conclusion

The biochemical & histological results demonstrated that the ethanolic extract of *A. marmelos* leaves has hepatoprotective activity against CCl₄ induced hepatotoxicity in mice. This needs to be further proved to get a lead compound with hepatoprotective nature.

Reference

[1] Gamble, J.S, 1993. Flora of the Presidency of Madras, Vol I-III, Bishen Singh Mahendra Pal Singh, Dehra Dun, India.

[2] Mathew, K.W, 1985. The Flora of Tamil Nadu Carnatic, The Rapinant Herbarium, St. Josephs College, Tiruchirapalli, India.

[3] Arul, S., Miyazaki and Dhananjayan, R, 2005. Studies on the anti-inflammatory, antipyretic and analgesic properties of the leaves of *Aegle marmelos*, J. Ethnopharmacol. 96: 159-163

[4] Shankarananth, V., Balakrishnan, N., Suresh, G., Sureshpandian, E., Edwin and Sheej, E, 2007. Analgesic activity of methanol extract of *Aegle marmelos* leaves, Fitoterapia 78: 258-259.

[5] Kamalakkannan, N., Stanely, P. and Prince, M, 2003. Hypoglycaemic effect of water extracts of *Aegle marmelos* fruits in streptozotocin diabetic rats, J. Ethnopharmacol. 87: 207-210.

[6] Arumugam, S., Kavimani, B., Kadalmani, A.B.A. Ahmed, M.A., Akbarsha and Rao, M.V, 2008. Antidiabetic activity of leaf and callus extracts of *Aegle marmelos* in rabbit, *Sci. Asia* 34: 317-321.

[7] Kesari, A.N., Gupta, R.K., Singh, S.K., Diwakar, S. and Watal, G, 2006. Hypoglycemic and antihyperglycemic activity of *Aegle marmelos* seed extract in normal and diabetic rats, J. Ethnopharmacol. 107: 374-379.

[8] Rana, B.K., Singh, U.P. and Taneja, V, 1997. Antifungal activity and kinetics of inhibition by essential oil isolated from leaves *Aegle marmelos*, J. Ethnopharmacol. 57: 29-34.

[9] Ulahannan, R.K., Thomas, T. and Sadasivan, C, 2008. Antibacterial action of leaves of *Aegle marmelos*, Int. J. (Sci.) 2: 134-138.

[10] Gangadevi, V. and Muthumary, J, 2008. Taxol, an anticancer drug produced by an endophytic fungus *Bartalinia robillardoides* Tassi, isolated from a medicinal plant, *Aegle marmelos* Correa ex Roxb, World J. Microbiol. Biotechnol. 24: 717-724.

[11] Singh, R. and Rao, H S, 2008. Hepatoprotective effect of the pulp/seed of *Aegle marmelos* Correa ex Roxb against carbon tetrachloride induced liver damage in rats, Int. J. Green Pharm. 2: 232-234.

[12] Karan, M., Vasisht, K. and Hanada, S.S, 1999. Antihepatotoxic activity of *Swertia chirata* on carbon tetrachloride induced hepatotoxicity in rats". Phytotherapy research. 13: 24-30.

[13] Chatterjee, T.K, 2000. "Medicinal plants with Hepatoprotective properties". Herbal options. Books and applied allied (P) Ltd., Calcutta, 143.

[14] Kakkar, P., Das, D. and Viswanathan, A. 1984. Modified spectrophotometric assay of superoxide dismutase. Ind J Biochem Biophys. 21: 130-32.

[15] Sinha, A.K, 1972. Colorimetric assay of catalase. Anal. Biochem 47: 389-394.

[16] Rotruck, T., Pope, A.L., Ganther, H.E., Swanson, A.B., Hafeman, D.G. and Hoekstra, W.G, 1973. Selenium: biochemical roles as a component of glutathione peroxidase. Science 179: 588 -590.

[17] Berton, T.R., Conti, C.J., Mitchell, D.L., Aldaz, C.M., Lubet, R.A. and Fischer, S.M, 1998. The effect of vitamin E acetate on ultraviolet induced mouse skin carcinogenesis. Mol. Carcinog. 23: 175-184.

- [18] Kleiner, D.E., Brunt, E.M., Van Natta, M., Behling, C., Contos, M.J., Cummings, O.W., Ferrell, L.D., Liu, Y.C., Torbenson, M.S., Unalp-Arida, A., Yeh, M., Mc Cullough, A.J., Sanyal, A.J, 2005. Nonalcoholic steatohepatitis clinical research network, design and validation of a histological scoring system for nonalcoholic fatty liver disease, *Hepatology* 41: 1313–1321.
- [19] Recknagel, R.O, 1983. A new direction in the study of carbon tetrachloride hepatotoxicity. *Life Sci.* 33: 401–408.
- [20] Recknagel, R.O., Glende, E.A. and Dolak, J.A, 1989. Mechanism of carbon tetrachloride toxicity. *Pharmacol Ther.* 43: 139-154.
- [21] Goepfert, A.R., Scheerens, H and Vermeulen, N.P., 1995. Oxygen and xenobiotic reductase activities of cytochrome P450. *Crit. Rev. Toxicol.* 25: 25–65.
- [22] Samudram, P., Rajeshwari, Hari., Vasuki, R., Geetha, A. and Sathiyamoorthi, P, 2008. Hepatoprotective activity of Bi - herbal ethanolic extract on CCl4 induced hepatic damage in rats. *African Journal of Biochemistry Research.* 2: 061-065.
- [23] Yu-Wen Hsu., China-Fang TAsi., Wen-Huei Chang., Yung-Chyuan Ho., Wen-Kang Chen. and fung-jou-Lu, 2008. Protective effect of *Dunaliella salina* – A Carotenoids-rich alga, against carbon tetrachloride induced hepatotoxicity in mice. *Food and Chemical Toxicity* 46: 3311 – 3317.
- [24] Sutha, D., Jegathambigai, R., Kumar, P. and Sudhakaran, S, 2010. A study on the hepatoprotective effect of *Andrographis paniculata* (burm.f) nees on mice. *Journal of Phytology.* 2(11): 25-30.