

Titanium lag screw osteosynthesis in the management of mandibular fractures

Shashidevi R. Haranal¹, Arati S Neeli^{2*}, R. K. Suryavanshi³, S M Kotrashetti² and Nitesh Naresh⁴

¹ Dept of Oral and Maxillofacial surgery, Saraswati - Dhanawantri Dental College and Hospital, Parbhani, India.

² Dept of Oral and Maxillofacial surgery, KLE VK Institute of Dental Sciences, Belgaum, India.

³Dept of Oral and Maxillofacial surgery, Al-Badar Rural Dental College and Hospital, Gulbarga, India.

⁴ Dental office, Army Dental Corps.

Abstract

Aims and objectives: To evaluate the efficiency of titanium lag screws in the management of oblique and sagittally displaced mandibular fractures. Also to analyze various complications encountered through this technique.

Materials and methods: Twenty cases presenting with mandibular oblique, sagittally displaced mandibular fractures requiring were selected in our study. Titanium lag screws were placed such that their axes bisect the angle between a perpendicular drawn to the fracture line and perpendicular to the bone surface. Postoperative follow up was done for 3 to 9 months

Results: Majority of the fractures (10) were parasymphysis fractures, 3 with associated fractures. Intermaxillary fixation was used in two of these cases as the fracture fragments were severely displaced (Table 1). In two patients, a single lag screw combined with a small conventional miniplate and a bone graft was used, due to loss of bone along the inferior border of the mandible in the fractured site. Two lag screws were used in severely displaced symphysis fractures and when two fracture sites were seen. Adequate rigidity and stability of fractured segments was achieved in all the cases.

Conclusion : Titanium lag screw fixation was found to have good rigidity, stability, economic and less time consuming in certain type of mandibular fractures, though there exists few contraindications regarding its usage. It is definitely a technique sensitive procedure, requiring strict adherence to the principle of lag screw placement and adequate knowledge about internal anatomy of the mandible.

Keywords: Mandible fractures, Lag screw, Rigid fixation.

INTRODUCTION

In maxillofacial trauma, mandibular fractures are more common to occur and frequently treated, than any other fracture of the facial skeleton. Operative treatment of mandibular fractures ideally include, reestablishing the correct occlusion, immediate uncompromised mandibular function. Unstable fixation methods often require intermaxillary fixation, which delays functional rehabilitation. Rigid internal fixation promotes primary bone healing without extended use of maxillomandibular fixation for immobilization.

It is generally accepted that reduction and fixation of the fracture to align the fragments in contact promotes bone healing. Moreover, a direct correlation between the fracture-gap width and the healing process is given in the literature; if the fracture-gap width is larger than 2 mm, then bone healing is delayed. Large fracture gaps cause a delay in fracture healing, as demonstrated in experimental and clinical investigations.¹ A good reduction of a fracture with small interfragmentary gaps is important for its revascularization and healing which can be achieved by rigid fixation²

Methods employed in rigid fixation include lag screw

technique, compression plates, reconstruction plate, non compression bone plates and external pin fixation. Fractures that follow a fairly straight course from buccal to lingual cortices lend themselves easily to compression plate osteosynthesis, but sagittal or oblique fractures should not be subjected to axial compression³. Sagittal and oblique fractures may be more amenable to repair with lag-screw techniques. To achieve optimal compression without displacement, a lag screw hole is drilled along a line as close to and perpendicular to the fracture line as possible. Compression is not used in cases of infection or comminution⁴. The goal of any operative treatment is, achievement of esthetic and functional preservation and restoration of occlusion.

Titanium lag screw fixation is the simplest means of rigid internal fixation by virtue of its ability to compress bone fragments without the use of a bone plate, and achieving great stability in majority of mandibular displaced or undisplaced fractures favouring more of oblique and sagittal fractures in symphysis, parasymphysis, body and angle fracture, being very technique sensitive it has not been widely used and therefore this study primarily emphasizes on its efficiency, based on established studies done.

Principle of lag screw fixation: The principle of the lag screw is based on axial compression of the bone fragments. The screw glides through the fragment located near the screw head (gliding hole) and seizes the fragment distant from the screw head (threaded hole).⁵ Lag screw should be placed such that their axes bisect the angle between a perpendicular drawn to the fracture line and perpendicular to the bone surface (Fig 1).

The major advantage of lag screw is that it can be applied more rapidly without decreasing the rigidity, allows a more anatomically accurate reduction. Displacement of bone fragments is

Received: July 15, 2012; Revised: Aug 20, 2012; Accepted: Sept 25, 2012.

*Corresponding Author

Dr. Arati S Neeli

Dept. of Oral and Maxillofacial surgery, KLE VK Institute of Dental Sciences, Belgaum-590010, India.

Email: aratiaqua@yahoo.co.in

much more common during the placement of bone plate, and almost never occurs while applying lag screw fixation⁶.

The study has been independently reviewed and approved by an ethical board. All participants have read and signed informed consent form.

MATERIALS AND METHODS

Twenty cases of mandibular fracture were selected which are indicated for lag screw fixation from 2005 to 2008. Oblique and laminar mandibular fractures which are simple or compound and displaced or undisplaced are included in the study. Cases selected were either single mandibular fracture or along with associated mandibular fractures. Fractures involving severe bone loss and Comminuted mandibular fracture along with other facial bone fractures are excluded from the study.

All the selected cases were treated by open reduction & internal fixation with titanium lag screws under general anesthesia or local anesthesia, as per the general systemic condition of the patient. A standard proforma was used to collect necessary information regarding each case. Neurological evaluation was done to rule out head injury, cervical spine injury and local nerve injuries if any.

General Physical examination was done to ascertain the presence or absence of any associated injury to thorax, abdomen, genitourinary tract and other bones of the body. Local Examination was done to see asymmetry, haemorrhage, laceration, tissue loss, abrasion, edema, echymosis, contour defects, CSF leak through the nose, mouth opening, deviation of the jaw, tenderness, step deformity, parasthesia and TMJ movements. In our study, we had seventeen male patients and three female patient, with an average age between 20yrs to 55yrs. Most of the cases gave alleged history of road traffic accident and few of assault. All the cases selected were oblique, symphysis or parasymphysis or body and simple or compound fractures. The maximum number of days after trauma was six days. Most of the patients, had pain and difficulty in mouth opening, occlusal derangement, facial asymmetry owing to swelling caused due to trauma. None of the patients, had preoperative infection at the fractured site and parasthesia also was not present.

Pre-operative Orthopantomogram, Posteroanterior mandible and occlusal views, for evaluation of fracture site of mandible and its displacement. Paranasal sinus and Submento vertex view were taken to rule out any associated midface fractures.

Besides routine blood, urine analysis and electrocardiogram were done in all cases & other investigations required for general anesthesia were carried out. Arch bar fixation was done in severely displaced fractures preoperatively. All our patients were operated either under General Anesthesia or Local anesthesia, using intraoral approach or extraoral lacerations. Titanium lag Screws of length 20 mm to 30 mm and Diameter of 2.3 mm & 2.7 mm are used.

With the help of Preoperative OPG the fracture site was identified (Fig 1, 2). Drill bits of corresponding sizes, for the lag screws were selected. An initial point of entry should be approximately 12 mm to 15mm anterior to the fracture, so that adequate angulation in superoinferior as well as mediolateral direction is done. The drill is placed almost perpendicular to the buccal cortex, to prevent skidding of the drill bit, at the selected point of entry initially, and then it is redirected to the required angulation based on the principle of lag screw insertion. The outer cortex followed by inner cortex is drilled with corresponding drill bits and countersinking is done at the outer cortex to adequately allow the

seating of the screw head. Once drilling is completed, thorough irrigation of the hole is done with normal saline before screw placement. Lag screw of appropriate size is selected and inserted completely with the help of screw holder (Fig3). Rigidity of fractured segments and occlusion is checked. The fracture site is closed. Antibiotics and analgesics were given postoperatively.

Patients in whom arch bar was put, was removed on the 2nd postoperative day. Follow up orthopantomogram was taken at 3 months to evaluate healing process radiographically (Fig4).

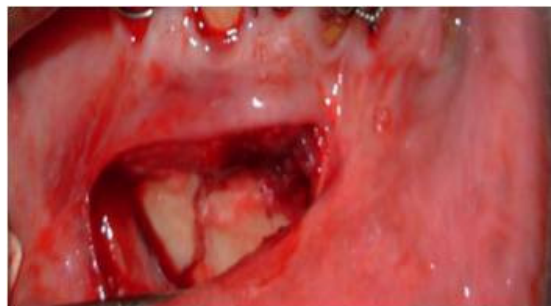

Fig 1. Fracture site



Fig 2. Preoperative OPG

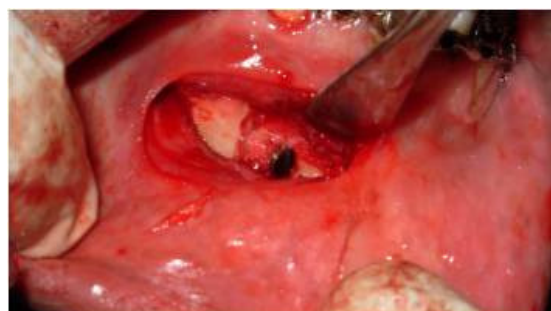

Fig 3. Lag screw fixation

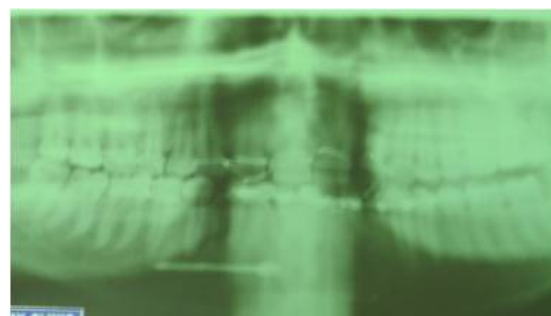


Fig 4. Postoperative OPG

RESULTS

Single or two titanium lag screws were placed depending on the site, amount of displacement between the fractured segments and number of fractures in each case. Majority of the fractures (10) were parasymphysis fractures, 3 with associated fractures. Intermaxillary fixation was used in two of these cases as the fracture fragments were severely displaced and severe occlusal derangement (Table1). In two patients, a single lag screw combined with a small conventional miniplate and a bone graft was used, due

to loss of bone along the inferior border of the mandible in the fractured site. Two lag screws were used in severely displaced symphysis fractures and when two fracture sites were seen. Follow up in our study ranged between 3 to 9 months. Adequate rigidity and stability of fractured segments was achieved in all the cases.

All the treated fractures were found to be stable at the follow up appointments and none of the cases developed postoperative infection or malocclusion during our follow up period. Postoperative radiographic evaluation showed good reduction in every patient.

Table 1. Operative procedure of the patients treated using Lag screw fixation

Case No.	Age	Sex	Diagnosis	Classification	Type of Anesthesia	Material Used		
						No. of Lag Screw	Other methods used	Management of Associated fractures
1	51	M	Symphysis	Simple	GA	1		-
2	58	F	Lt. Parasymphysis & Rt. Condyle	Compound	GA	2		IMF
3	48	M	Lt. body	Simple	GA	1	Miniplate with graft	-
4	43	M	Symphysis	Compound	LA	2		-
5	28	M	Lt. Parasymphysis	Simple	LA	1		-
6	22	M	Symphysis	Compound	GA	2		-
7	45	M	Lt. Parasymphysis	Compound	LA	1		-
8	32	M	Symphysis & Lt. Angle	Simple	LA	2		-
9	29	M	Rt. Parasymphysis & Lt. Angle	Compound	LA	2		-
10	35	M	Rt. Parasymphysis	Simple	LA	1		-
11	42	M	Lt. Parasymphysis	Compound	GA	1	Miniplate with graft	-
12	38	M	Symphysis	Simple	LA	1		-
13	41	M	Lt. Parasymphysis	Compound	GA	1		-
14	28	M	Symphysis	Compound	GA	2		-
15	25	M	Rt. Parasymphysis & Lt. Angle	Compound	GA	1		IMF
16	44	M	Symphysis	Compound	GA	2		-
17	25	M	Rt. Parasymphysis	Compound	LA	1		-
18	35	M	Lt. Parasymphysis	Compound	LA	1		-
19	59	M	Rt. body	Compound	GA	1		-
20	32	M	Symphysis & Lt. Angle	Simple	GA	2		-

DISCUSSION

One of the most frequent treatments provided by oral & maxillofacial surgeons is the management of mandibular fractures. Operative treatment of mandibular fractures ideally include, reestablishing the correct occlusion and immediate uncompromised mandibular function. Unstable fixation methods often require intermaxillary fixation, which delays functional rehabilitation.⁷ Rigid internal fixation promotes primary bone healing without extended use of maxillomandibular fixation for immobilization.

We have not faced the difficulty of displacement of bone fragments in our patients while applying lag screw fixation which is much more common during the placement of bone plate. Titanium lag screws as a type of rigid fixation has several unique advantages over boneplate fixation. The major advantage is that lag screw can be applied more rapidly without decreasing the rigidity, allows a more anatomically accurate reduction without displacement of fragments.⁸ It is important to understand that the stability of this kind of osteosynthesis relies solely on compression between the fragments. If there is fragmentation this single stabilizing factor is lost and the fracture must be treated with bone plates and screws in neutral position.⁹

Eliminating maxillomandibular fixation generally results in greater patient satisfaction because of decreased postoperative discomfort, earlier return to normal jaw function, easier maintenance of oral hygiene and better nutrition.¹⁰ Intermaxillary fixation (IMF) was used in two cases only, as both the patients had additional

mandibular fractures with severe occlusal derangement but IMF was removed on the 2nd postoperative day to facilitate early functioning.

Neiderdellman 1981 has described the use of a single unprotected lag screw for the fixation of transverse fractures of the angle of the mandible. Spiessl has recommended the use of lag screws in oblique fracture of the body of the mandible.⁶

In our study as some of the symphysis fractures were not stable after single lag screw placement, an additional screw was placed. According to Ardary the ultimate stability of screw fixation is dependant on the number of screws used, method of screw placement, bicortical placement of screws and the holding power of screws, which is affected by cortical bone thickness. Ideally the length of fracture surface should be greater or equal to the mandibular height in oblique surface fractures. Spiessl states that the length of fracture should be atleast twice the height of the mandible, in atrophic mandibles.¹

Lag screw can be used alone or as a supplement to plate osteosynthesis dependant on the anatomy of fracture site.¹² In our study, in two patients, the treatment plan was modified and a single lag screw was supplemented with a conventional miniplate (2.00mm) due to bone loss at the inferior border of the mandible. Whenever a plate is used to repair an oblique fracture with overlapping fragments, any screws passing through the overlapping fragments must be placed using lag screw techniques, otherwise they will tend to distract the fracture segments. The plate here serves merely to increase the structural strength of bone in this area and thereby relieve stress on the fracture weakened area.¹³

Studies suggested that rigid internal fixation results in lower rate of infection, lesser chances of malunion and non union when compared with standard treatment. A lower incidence of infection due to absence of interfragmentary mobility has been reported is also an advantage of this technique.¹⁴ Rigid internal fixation patients who are non complaint may have a lower risk of developing malunion, nonunion or infection than non complaint patients treated by standard therapy.¹⁵ In the postoperative follow up period all the patients in our study showed satisfactory bone healing without any signs of infection, malunion and nonunion. One patient had lingual cortical perforation, but there was no soft tissue perforation and the patient didn't have any postoperative complaints, hence it was left in place and retrieval was not planned. The other patient had developed transient Bell's palsy due to facial nerve injury because of associated condylar fracture, on the opposite side.

In our study when we observed the time factor, which was far less when compared to the adaptation and fixation of bone plate and cost economic too, along with patients satisfaction due to immediate release of intermaxillary fixation. In one of the cases patient had post operative tingling sensation at the site of associated mandibular angle fracture, in rest of the treated patients, in our study none developed significant postoperative complications like, infection, occlusal disturbance, sensory disturbances, malunion, nonunion, mobility of the screw or bone fragments during the follow up period.

However, there are circumstances where the lag screws are contraindicated. The most important is when there is comminution and or bone loss in the fracture gap, in such situations, applying a bone plate without compression across this gap can achieve rigid fixation without disturbing the occlusion.¹⁶ Communitated fractures and with severe bone loss were excluded from our study and two patients with bone loss at the lower border were supplemented with bone graft and plate fixation at the inferior border.

In the current era of increasing medical costs, our study shows a promising useful application of titanium lag screws in oblique or sagittally displaced mandibular fractures, which gives optimum stability, rigidity, requires less time and cost effective also, in the hands of an experienced surgeon.

CONCLUSION

Lag-screw fixation is a safe and effective method that has a number of advantages over plate osteosynthesis. Besides supplying compression between the fragments to support healing, fracture stabilization is firm, and tissue exposure is reduced. A unique advantage of lag screw over 1-plate fixation is that it can be applied more rapidly.

REFERENCES

[1] Claes L, Grass R, Schmickal T, Kisse B, Eggers C, Gerngross H, et al. 2002. Monitoring and healing analysis of 100 tibial shaft

fractures. *Langenbecks Arch Surg.* 387:146-152.

- [2] Claes L, Eckert-Hubner K, Augat P. 2003. The fracture gap size influences the local vascularization and tissue differentiation in callus healing. *Langenbecks Arch Surg.* 388:316-322
- [3] Ellis E. 1996. Complications of rigid internal fixation for mandible fractures. *J. Craniomaxillofac Trauma.* 2:32-39.
- [4] Kearns GJ, Perrott DH, Kaban LB. 1994. Rigid fixation of mandible fractures: does operator experience reduce complications? *J. Oral Maxillofac Surg.* 52:226-231.
- [5] Heidrun schaff et al, 2011. "Comparison of miniplate versus lag-screw osteosynthesis for fractures of the mandibular angle" - *Oral Surgery, Oral Medicine, Oral Pathology, Oral Radiology* -Volume 111, Issue 1, Pages 34-40.
- [6] Ellis E, Ghali GE. 1991. Lag screw fixation of mandibular angle fractures. *J Oral Maxillofac Surg.* 49: 234-243.
- [7] John, Ellis, Daniel, Laskin, 1994. "Analysis of Seating and Fracturing Torque of Bicortical screws" *J. Oral Maxillofacial surgery*, 52 :483-486.
- [8] Ellis, Ghali 1991. "Lag screw fixation of anterior mandibular fracture" : *Journal of Oral & maxillofacial surgery* - Jan 49:13-21.
- [9] Kallela et al, 1996. Tateyuki Ilzuka, Pekka Laine, "Lag -screw fixation of mandibular parasymphiseal and angle fractures": *Oral Surgery, Oral Medicine, Oral Pathology*, Vol-82(5): 510-16.
- [10] Thomas, Dodsan, David, 1990. "Fixation of Mandibular Fractures: A comparative Analysis of Rigid Internal Fixation Standard Fixation techniques" *J. Oral Maxillofacial surgery* 48: 362 - 366.
- [11] Zachariades, Mezitis, Papademetriou, 1996. "Use of lag screws for the management of mandibular trauma": *Oral Surgery Oral Medicine Oral Pathology*. 81(2):164-167.
- [12] John Jones, Joseph, Van Sickels, 1988. "Rigid fixation: A review of concepts and treatment of fractures" *Oral Surgery*, Vol-65 (1): 13 - 18.
- [13] Myer S. Leonard, 1987. "The Use of Lag Screws in Mandibular Fractures": *The Otolaryngologic Clinics of North America*-Vol.20, No. 3.
- [14] Leon A. Assael, 1993. "Evaluation of Rigid Internal Fixation of Mandible Fractures Performed in the Teaching laboratory": *Journal of Oral Maxillofacial surgery*, 51:1315-1319.
- [15] Thomas B. Dodson, David H. Perrott, Leonard B. Kaban, 1990. "Fixation of Mandibular Fractures" : *Journal Of Maxillofacial Surgery*, 48:362-366.
- [16] Edward Ellis, G.E Ghali, 1991. "Lag Screw Fixation of Mandibular Angle Fractures" *Journal of Oral &Maxillofacial Surgery* -49:234-243.